


- *Structural Allograft Versus Synthetic Interbody Cage for Anterior Cervical Discectomy and Fusion: A Comparison of 1-Year Outcomes From a National Database (2020)*
- *Structural Allograft versus Polyetheretherketone Implants in Patients Undergoing Spinal Fusion Surgery: A Systematic Review and Meta-Analysis (2020)*
- *Fivefold higher rate of pseudarthrosis with polyetheretherketone interbody device than with structural allograft used for 1-level anterior cervical discectomy and fusion (2018)*
- *Cages in ACDF are Associated With a Higher Nonunion Rate Than Allograft (2018)*
- *PEEK-Halo effect in interbody fusion (2015)*
- Articles in Review:
  - *Greater risk of pseudarthrosis using PEEK spacers vs structural allografts in 1-level ACDF*
  - *Higher nonunion rate using cages versus allografts in ACDF*
  - *Lower revision rate with structural allografts vs synthetic cages in multilevel ACDF procedures*
  - *Structural allografts provide better outcomes than PEEK cages in spinal fusion procedures*

# Structural Allograft Versus Synthetic Interbody Cage for Anterior Cervical Discectomy and Fusion: A Comparison of 1-Year Outcomes From a National Database

Nandakumar Menon, MD<sup>1</sup> , Justin Turcotte, PhD, MBA<sup>1</sup>,  
and Chad Patton, MD, MSc<sup>1</sup> 

Global Spine Journal

1-8

© The Author(s) 2020

Article reuse guidelines:

sagepub.com/journals-permissions

DOI: 10.1177/2192568220942217

journals.sagepub.com/home/gsj



## Abstract

**Study Design:** Observational cohort study.

**Objective:** To compare 1-year perioperative complications between structural allograft (SA) and synthetic cage (SC) for anterior cervical discectomy and fusion (ACDF) using a national database.

**Methods:** The TriNetX Research Network was retrospectively queried. Patients undergoing initial single or multilevel ACDF surgery between October 1, 2015 and April 30, 2019 were propensity score matched based on age and comorbidities. The rates of 1-year revision ACDF surgery and reported diagnoses of pseudoarthrosis, surgical site infection (SSI), and dysphagia were compared between structural allograft and synthetic cage techniques.

**Results:** A comparison of 1-year outcomes between propensity score matched cohorts was conducted on 3056 patients undergoing single-level ACDF and 3510 patients undergoing multilevel ACDF. In single-level ACDF patients, there was no difference in 1-year revision ACDF surgery ( $P = .573$ ), reported diagnoses of pseudoarthrosis ( $P = .413$ ), SSI ( $P = .620$ ), or dysphagia ( $P = .529$ ) between SA and SC groups. In multilevel ACDF patients, there was a higher rate of revision surgery (SA 3.8% vs SC 7.3%, odds ratio = 1.982,  $P < .001$ ) in the SC group, and a higher rate of dysphagia in the SA group (SA 15.9% vs SC 12.9%).

**Conclusion:** While the overall revision and complication rate for single-level ACDF remains low despite interbody graft selection, SC implant selection may result in higher rates of revision surgery in multilevel procedures despite yielding lower rates of dysphagia. Further prospective study is warranted.

## Keywords

anterior cervical discectomy and fusion, ACDF, structural allograft, interbody spacer, surgical site infection, pseudoarthrosis

## Introduction

Anterior cervical discectomy and fusion (ACDF) has emerged as the most commonly performed surgical treatment for degenerative cervical spine disease.<sup>1</sup> Each year, over 132 000 ACDFs are performed in the United States and volumes have increased 5.7% annually from 2006 to 2013.<sup>2</sup> Since early descriptions of anterior surgical approaches in the 1950's, advancements in techniques, instrumentation, and implant materials have focused primarily on achieving more reliable fusion of unstable or symptomatic segments.<sup>3-5</sup> Options for interbody grafts have evolved from tricortical

iliac crest autograft to structural allograft (SA) or synthetic cages (SC) of various materials.

Autograft harvested from the iliac crest is biocompatible and nonimmunogenic and has been reported to have high

<sup>1</sup> Anne Arundel Medical Center, Annapolis, MD, USA

### Corresponding Author:

Nandakumar Menon, AAMC Orthopedics, Anne Arundel Medical Center, 2000 Medical Parkway, Suite 101, Annapolis, MD 21401, USA.  
Email: nmenon@aahs.org



Creative Commons Non Commercial No Derivs CC BY-NC-ND: This article is distributed under the terms of the Creative Commons Attribution-Non Commercial-NoDerivs 4.0 License (<https://creativecommons.org/licenses/by-nc-nd/4.0/>) which permits non-commercial use, reproduction and distribution of the work as published without adaptation or alteration, without further permission provided the original work is attributed as specified on the SAGE and Open Access pages (<https://us.sagepub.com/en-us/nam/open-access-at-sage>).

fusion rates with relatively few incidences of graft complications.<sup>5-7</sup> Hence, autograft is considered to be the gold standard for ACDF. However, in addition to a second surgical site with increased blood loss and operative time, the donor site is frequently reported to have complications such as pain, hematomas, seromas, infections, and fractures contributing to potential functional disability.<sup>8,9</sup>

The potential for graft site complications and additional operative time has led surgeons to increasingly substitute autograft with structural allograft or synthetic cages of various materials such as polyetheretherketone (PEEK) and titanium alloys.<sup>10,11</sup> In a retrospective review examining geographic variation in anterior cervical fusion procedures, McGuire et al<sup>12</sup> demonstrated a marked decrease in autograft utilization from 86% in 1999 to 10% in 2008. During the same time period, they reported a significant increase in the use of structural allograft and synthetic cages from 14% to 59% and 0% to 31%, respectively. In a 2017 international survey of spine surgeons, PEEK cages (64.1%) were the most commonly used interbody implant worldwide.<sup>11</sup> While respondents universally agreed that achieving fusion was successful to a good clinical outcome, only half of respondents were satisfied with comparative effectiveness data available on graft materials.

While the use of structural allograft and synthetic cages for single- and multilevel ACDF has been individually reported in multiple studies with favorable outcomes,<sup>13-15</sup> there are few direct comparisons of complications and rates of revision surgery between structural allografts and synthetic cages. Krause et al<sup>16</sup> recently reported that the use of PEEK implants in single-level ACDF is associated with significantly higher rate of pseudoarthrosis and need for revision surgery when compared with the use of structural allografts. In their study, 29 of 56 (51.8%) PEEK implants demonstrated radiographic evidence of pseudoarthrosis compared to 7 of 71 (10%) structural allograft. Furthermore, 7 patients from the PEEK group required revision (12.5%) while 1 patient with structural allograft required revision (1.4%). To increase sample size, other authors have utilized a large-scale administrative database (PearlDiver Patient Record Database) to compare outcomes between structural allograft and synthetic cages.<sup>17,18</sup> Goz et al<sup>17</sup> included 17 000 patients from 2007 to 2014, while Pirkle et al<sup>18</sup> included 6130 patients from 2007 to 2016. After correcting for age, gender, comorbidity burden, and number of levels fused, Goz et al<sup>17</sup> reported that graft choice was not an independent predictor of complications, with an overall rate of revision surgery of <1% in both groups. In contrast, Pirkle et al<sup>18</sup> found a higher rate of revision surgery for synthetic cages (5.32%) compared with structural allograft (1.97%), and this difference remained significant after controlling for confounding variables such as levels fused and smoking status.

In an era of maximizing value, our objective was to further understand potential differences in one-year clinical outcomes between structural allograft and synthetic cages. We selected the TriNetX platform, a multicenter, longitudinal database, to obtain the most recent comparative data across a large patient sample.

## Methods

This research was deemed exempt from institutional review board review by the institution's clinical research committee. The TriNetX Research database was retrospectively queried as of May 22, 2020 to evaluate all patients undergoing single or multilevel ACDF surgery between October 1, 2015 and April 30, 2019. All patients had a minimum of one-year follow up data available, and the study time period aligned with the implementation of International Classification of Diseases 10th edition (ICD-10) to maintain consistency in code-based definitions. Patients were then grouped by receipt of structural allograft or synthetic cage. Analysis was performed using propensity score matched cohorts. Propensity score matching was performed based on age, race, gender, and the presence or absence of the following diagnoses within the year prior to ACDF surgery: cervical disc disorders; spondylosis; cervical radiculopathy; hypertension; chronic pain; anxiety, dissociative, stress-related, somatoform and other nonpsychotic mental disorders; diabetes mellitus, mood (affective) disorders; overweight or obesity; nicotine dependence; disorders of bone density and structure, and malnutrition. The primary outcome measure was revision ACDF surgery within 1 year of the initial procedure. Revision surgeries included ACDF, posterior decompression and fusion, posterior decompression without fusion and other procedures (osteotomy, posterior open treatment of fracture or dislocation, laminectomy for lesions and neoplasm, anterior decompression). Secondary outcome measures included reported diagnoses of pseudoarthrosis, surgical site infection (SSI), or dysphagia within the 1-year postoperative period. Adjacent segment disease was considered for evaluation as a secondary endpoint but excluded due to the lack of a specific ICD-10 code for this condition. Primary and secondary outcomes were identified by relevant diagnosis or procedure codes. A full list of definitions for the surgical procedures, comorbidities, and outcomes is presented in Table 1. All statistical analysis was performed using TriNetX Analytics. Significance was assessed at an alpha of .05.

## About TriNetX

TriNetX is a "global health research network that optimizes clinical research and enables discoveries through the generation of real-world evidence."<sup>19</sup> The research platform includes longitudinal data from 26 health care organizations and includes over 37 million patients. As a federated network, TriNetX received a waiver from Western Institutional Review Board since only aggregated counts, statistical summaries of de-identified information, but no protected health information is received, and no study-specific activities are performed in retrospective analyses. De-identified, HIPAA (Health Insurance Portability and Accountability Act) compliant electronic health record (EHR) data is collected from participating health care organizations who submit structured and unstructured data elements. On average, participants submit data retrospectively for 7 years, with some providing historical data 13 years or

**Table 1.** Coding Definitions: CPT and ICD-10 Code Definitions Provided for Single-Level Structural Allograft and Synthetic Interbody Spacer, Multilevel Structural Allograft and Synthetic Interbody spacer, Patient Comorbidities, and Procedure Outcomes.

CPT and ICD-10 code definitions	
<i>Surgical procedures</i>	
Single level with structural allograft	22 551 (ACDF) and 20 931 (structural allograft) and cannot have 22 552 (multilevel) or 22 853 (biomechanical spacer); and cannot have any history of previous 22 551 or 22 552 (no prior ACDF)
Single level with interbody spacer	22 551 (ACDF) and 22 853 (biomechanical spacer) and cannot have 20 931 (structural allograft) or 22 552 (multilevel); and cannot have any history of previous 22 551 or 22 552 (no prior ACDF)
Multilevel with structural allograft	22 551 (ACDF) and 20 931 (structural allograft) and 22 552 (multilevel) and cannot have 22 853 (biomechanical spacer); and cannot have any history of previous 22 551 or 22 552 (no prior ACDF)
Multilevel with interbody spacer	22 551 (ACDF) and 22 853 (biomechanical spacer) and 22 552 (multilevel) and cannot have 20 931 (structural allograft); and cannot have any history of previous 22 551 or 22 552 (no prior ACDF)
<i>Comorbidities and risk factors (diagnosis present 1 day to 1 year prior to surgery)</i>	
Spondylosis	M47
Cervical disc disorders	M50
Radiculopathy, cervical region	M54.12
Chronic pain, not elsewhere classified	G89.2
Hypertensive diseases	I10-I16
Anxiety, dissociative, stress-related, somatoform and other nonpsychotic mental disorders	F40-F48
Mood (affective) disorders	F30-F39
Overweight and obesity	E66
Diabetes mellitus	E08-E13
Nicotine dependence	F17
Disorders of bone density and structure	M80-85
Malnutrition	E40-46
<i>Outcomes (diagnosis or procedure present 1 day to 1 year after surgery)</i>	
Revision	22 210, 22 216, 22 226, 22 326, 22 548, 22 551, 22 552, 22 590, 22 595, 22 600, 22 614, 63 001, 63 015, 63 020, 63 035, 63 040, 63 043, 63 045, 63 048, 63 050, 63 051, 63 075, 63 076, 63 250, 63 265, 63 270, 63 275, 63 280, 63 285
Pseudoarthrosis	M96.0
Dysphagia	R13
Surgical site infection	T81.4

Abbreviations: CPT, Current Procedural Terminology; ICD-10, International Classification of Diseases–10th Revision; ACDF, anterior cervical discectomy and fusion.

older. Variables captured include demographics, diagnoses (all mapped to ICD-10 coding) procedures (ICD-10 PCS and CPT), medications, lab values, and genomics information. Statistical analysis is performed within the analytics platform using parallel R and Python queries triangulated to maximize test accuracy.<sup>19</sup>

## Results:

A total of 8103 patients were included in this observational cohort study. Of the 3775 patients undergoing single-level ACDF, structural allograft was used in 2213 (59%) patients and synthetic cages in 1562 (41%) patients. Of the 4328 multilevel ACDF procedures, structural allograft (SA) was used in 2482 (57%) patients and synthetic cages (SC) in 1846 (43%) patients.

To control for differences in comorbidities across the sample, the cohorts were propensity score matched based on age, gender, race, and comorbid conditions. Prior to propensity score matching, patients undergoing single-level ACDF using structural allograft were significantly younger (SA  $53.9 \pm 12.9$  vs SC  $55.1 \pm 13.0$  years,  $P = .004$ ), had higher rates of cervical disc disorders (SA 62.7% vs SC 59.0%,  $P = .020$ ), higher rates of cervical radiculopathy (SA 43.6% vs SC 40.2%,  $P = .040$ ), higher rates of nicotine dependence (SA 17.6% vs SC 10.7%,  $P < .001$ ), lower rates of spondylosis (SA 49.9% vs SC 55.1%,  $P = .002$ ), and lower rates of disorders of bone density and structure (SA 4.4% vs SC 6.7%,  $P = .002$ ). After propensity score matching, no significant differences remained (Table 2). Prior to propensity score matching, patients undergoing multilevel ACDF using synthetic cage were significantly

**Table 2.** Patient Characteristics and Comorbidities Before and After Propensity Score Matching: Demographics and Comorbidities Data Provided for Single- and Multilevel ACDF With the Original Cohorts and Propensity Score Matched Cohorts.

Single-level ACDF	Initial sample			Propensity score matched cohort		
	Structural allograft (n = 2213), n (%)	Synthetic interbody spacer (n = 1562), n (%)	P <sup>a</sup>	Structural allograft (n = 1528), n (%)	Synthetic interbody spacer (n = 1528), n (%)	P <sup>a</sup>
Demographics and comorbidities						
Age, years, mean $\pm$ SD	53.9 $\pm$ 12.9	55.1 $\pm$ 13.0	<b>.004</b>	55.2 $\pm$ 12.9	55.0 $\pm$ 13.0	.609
White race	1797 (81.2)	1270 (81.3)	.936	1245 (81.5)	1240 (81.2)	.817
Female gender	1021 (46.1)	757 (48.5)	.158	736 (48.2)	737 (48.2)	.971
Cervical disc disorders	1388 (62.7)	921 (59.0)	<b>.020</b>	905 (59.2)	910 (59.6)	.854
Spondylosis	1105 (49.9)	861 (55.1)	<b>.002</b>	850 (55.6)	828 (54.2)	.424
Cervical radiculopathy	964 (43.6)	628 (40.2)	<b>.040</b>	611 (40.0)	624 (40.8)	.632
Hypertension	836 (37.8)	611 (39.1)	.404	578 (37.8)	592 (38.7)	.602
Chronic pain	457 (20.7)	343 (22.0)	.333	340 (22.3)	328 (21.5)	.599
Anxiety, dissociative, stress-related, somatoform and other nonpsychotic mental disorders	354 (16.0)	263 (16.8)	.491	246 (16.1)	248 (16.2)	.922
Mood (affective) disorders	383 (17.3)	253 (16.2)	.370	252 (16.5)	248 (16.2)	.845
Diabetes mellitus	373 (16.9)	251 (16.1)	.522	245 (16.0)	248 (16.2)	.883
Overweight or obese	295 (13.3)	187 (12.0)	.218	177 (11.6)	185 (12.1)	.654
Nicotine dependence	389 (17.6)	167 (10.7)	<b>&lt;.001</b>	179 (11.7)	167 (10.9)	.493
Disorders of bone density and structure	97 (4.4)	104 (6.7)	<b>.002</b>	82 (5.4)	88 (5.8)	.636
Malnutrition	30 (1.4)	13 (0.8)	.136	12 (.8)	13 (.9)	.841

Multilevel ACDF	Initial sample			Propensity score matched cohort		
	Structural allograft (n = 2482), n (%)	Synthetic interbody spacer (n = 1846), n (%)	P	Structural allograft (n = 1755), n (%)	Synthetic interbody spacer (n = 1755), n (%)	P
Demographics and comorbidities						
Age, years, mean $\pm$ SD)	55.8 $\pm$ 11.0	57.8 $\pm$ 10.9	<b>&lt;.001</b>	57.4 $\pm$ 10.8	57.3 $\pm$ 10.8	.731
White race	1966 (79.2)	1527 (82.7)	<b>.004</b>	1423 (81.1)	1438 (81.9)	.514
Female gender	1197 (48.2)	925 (50.1)	.221	847 (48.3)	869 (49.5)	.458
Cervical disc disorders	1444 (58.2)	1175 (63.7)	<b>&lt;.001</b>	1109 (63.2)	1100 (62.7)	.753
Spondylosis	1674 (67.4)	1283 (69.5)	.150	1201 (68.5)	1215 (69.2)	.636
Cervical radiculopathy	1258 (50.7)	848 (45.9)	<b>.002</b>	815 (46.4)	817 (46.5)	.946
Hypertension	1081 (43.6)	822 (44.5)	.523	780 (44.4)	770 (43.9)	.734
Chronic pain	531 (21.4)	502 (27.2)	<b>&lt;.001</b>	430 (24.5)	448 (25.5)	.483
Anxiety, dissociative, stress-related, somatoform and other nonpsychotic mental disorders	427 (17.2)	334 (18.1)	.447	308 (17.6)	316 (18.0)	.724
Mood (affective) disorders	435 (17.5)	350 (19.0)	.226	314 (17.9)	322 (18.3)	.726
Diabetes mellitus	423 (17.0)	319 (17.3)	.837	302 (17.2)	303 (17.3)	.964
Overweight or obese	375 (15.1)	250 (13.5)	.147	229 (13.0)	240 (13.7)	.585
Nicotine dependence	423 (17.0)	222 (12.0)	<b>&lt;.001</b>	201 (11.5)	219 (12.5)	.349
Disorders of bone density and structure	123 (5.0)	143 (7.7)	<b>&lt;.001</b>	110 (6.3)	121 (6.9)	.454
Malnutrition	31 (1.3)	10 (0.5)	<b>.018</b>	11 (0.6)	10 (0.6)	.827

Abbreviation: ACDF, Anterior cervical discectomy and fusion.

<sup>a</sup> Statistical significance with  $P < .05$  in boldface.

older (SA  $55.8 \pm 11.0$  vs SC  $57.8 \pm 10.9$  years,  $P < .001$ ), more likely to be White (SA 79.2% vs SC 82.7%,  $P = .004$ ) and had higher rates of cervical disc disorders (SA 58.2% vs SC 63.7%,  $P < .001$ ), higher rates of chronic pain (SA 21.4% vs SC 27.2%,  $P < .001$ ), higher rates of disorders of bone density and structure (SA 5.0% vs SC 7.7%,  $P < .001$ ), lower rates of cervical radiculopathy (SA 50.7% vs SC 45.9%  $P = .002$ ), lower rates of nicotine dependence (SA 17.0% vs. SC 12.0%,

$P < .001$ ), and lower rates of malnutrition (SA 1.3% vs SC 0.5%,  $P = .018$ ). After propensity score matching none of these differences remained (Table 2).

Following propensity score matching, 3056 patients underwent single-level ACDF, with 1528 (50%) patients in the structural allograft group and 1528 (50%) in the synthetic cage group. Comparing 1-year outcomes, there was no difference in the rate of revision surgery ( $P = .573$ ) or reported diagnoses

**Table 3.** Propensity Score Matched Cohorts, 1-Year Outcomes: Data Provided for Propensity Score Matched Patient Cohorts With Single- and Multilevel ACDF Utilizing Structural Allograft or Synthetic Interbody Spacer.

	Structural allograft, n (%)	Synthetic interbody spacer, n (%)	Odds Ratio (95% CI)	<i>P</i> <sup>a</sup>
Single level (n = 3056)	1528 (100.0)	1528 (100.0)		
Revision	56 (3.7)	62 (4.1)	1.112 (0.769-1.607)	.573
Pseudoarthrosis	232 (15.2)	216 (14.1)	0.920 (0.753-1.124)	.413
Surgical site infection	17 (1.1)	20 (1.3)	1.179 (0.615-2.259)	.620
Dysphagia	177 (11.6)	166 (10.9)	0.930 (0.743-1.165)	.529
Multilevel (n = 3510)	1755 (100.0)	1755 (100.0)		
Revision	67 (3.8)	128 (7.3)	1.982 (1.464-2.684)	<b>&lt;.001</b>
Pseudoarthrosis	372 (21.2)	413 (23.5)	1.144 (0.976-1.341)	.097
Surgical site infection	18 (1.0)	23 (1.3)	1.281 (0.689-2.383)	.432
Dysphagia	279 (15.9)	226 (12.9)	0.782 (0.647-0.945)	<b>.011</b>

Abbreviation: ACDF, anterior cervical discectomy and fusion.

<sup>a</sup>Statistical significance with *P* < .5 in boldface.

of pseudoarthrosis (*P* = .413), SSI (*P* = .620), or dysphagia (*P* = .529) (Table 3).

A total of 3510 patients remained in the multilevel ACDF cohort following propensity score matching, with equal distribution among the SA and SC groups. For patients in the SC group, there was a higher likelihood of revision surgery (SA 3.8% vs SC 7.3%, OR = 1.982, *P* < .001) and lower likelihood of dysphagia (SA 15.9% vs SC 12.9%, OR = 0.782, *P* = .011). No significant differences in SSI (*P* = .439) or pseudoarthrosis (*P* = .097) were observed (Table 3).

## Discussion

Outcomes following ACDF have been shown to be effective in patients with degenerative cervical disease.<sup>5,13,20</sup> With an increasing number of synthetic cage materials and implants available to surgeons, our study represents an analysis of the most recent data available comparing 1-year complications between structural allografts and synthetic cages. Compared with structural allograft, patients undergoing multilevel ACDF with synthetic cage were at increased risk for 1-year revision surgery, while those receiving structural allograft were at increased risk for dysphagia.

For single-level ACDF, our comparison of 1-year outcomes between structural allografts and synthetic cages did not reveal any differences in the risk of revision surgery, pseudoarthrosis, SSI, or dysphagia. In contrast to our results, Krause et al<sup>16</sup> demonstrated radiographically higher rate of pseudoarthrosis (SA 10% vs PEEK 51.8%, *P* < .001) and greater need for revision surgery (SA 1.4% vs PEEK 12.5%, *P* = .01) with the use of PEEK in single-level ACDF. Based on these results, Krause and colleagues concluded that PEEK devices are associated with significantly higher rates of pseudoarthrosis and need for revision surgery compared with the use of allograft for single-level ACDF. Similarly, an administrative database study by Pirkle et al<sup>18</sup> suggested the use of structural allograft to be superior over synthetic cages after finding higher pseudoarthrosis rates in patients who underwent single-level ACDF

with synthetic cages compared to structural allograft (SA 1.9% vs SC 4.2%, *P* = .0007) after controlling for number of levels treated, diabetes status, and tobacco use. We posit that our results may have deviated from these findings given the relatively low rates of complications observed in our cohort of single-level ACDFs, especially over the 1-year time horizon. In addition, our study employed more extensive propensity score matching than the Pirkle and Krause studies, suggesting that previously unexamined comorbidities and risk factors beyond smoking status, sex, diabetes, age, and body mass index—which were controlled for in the prior studies—may be important in determining the optimal implant for single-level ACDF.

Previous studies have observed significantly higher rates of pseudoarthrosis and need for revision surgery in multilevel ACDF compared to single-level ACDF utilizing structural allografts and synthetic cages.<sup>21-23</sup> In our present comparative study, we observed higher rates of pseudoarthrosis and likelihood of revision surgery in the multilevel ACDF cohort. Our results further show that the patients who underwent multilevel ACDF with synthetic cages have a significantly higher likelihood of revision surgery when compared with structural allografts. Our results are directionally in line with the Pirkle et al<sup>18</sup> comparative review which demonstrated significantly higher pseudoarthrosis rate with 2-level (SA 1.7% vs SC 6.1%, *P* < .001), and 3+ level (SA 2.9% vs SC 6.3%, *P* < .001) ACDF. Similar to this study,<sup>18</sup> we included both anterior and posterior procedures in our criteria for revision surgery in order to broadly capture these clinical scenarios.

In another comparison, Goz et al<sup>17</sup> evaluated the rate of perioperative complications in patients undergoing ACDF found a statistically significant correlation with larger overall rate of complications in the synthetic cage (SA 7.76% vs SC 8.71%, *P* < .01) group and higher likelihood of revision surgery in the structural allograft (SA 0.56% vs SC 0.50%, *P* = .03) group. However, the authors considered these differences to be clinically insignificant given the low absolute differences observed. Based on these results, they concluded that synthetic



cages are associated with a marginally higher overall rate of complications with similar revision rates, but acknowledged that additional large studies are necessary to further elucidate which graft combination provides the ultimate combination of fusion rates, low complications, and low cost. In contrast, our study showed significantly higher revision rate with synthetic cages in multilevel ACDF that may affect clinical practice. Beyond revision rate, our study evaluated the secondary outcomes of SSI, pseudoarthrosis, and dysphagia. While no significant differences between the structural allograft and synthetic cage groups were observed, with the exception of dysphagia in multilevel surgeries, these endpoints are limited in that they are grossly underreported postoperatively. In addition, the broad evaluation of SSI encompasses a wide variety of complications from benign superficial infections to deep infections requiring surgical intervention. Our observation of higher rates of dysphagia in patients undergoing multilevel ACDF with structural allograft is in alignment with Goz et al's evaluation of dysphagia rates in the single- and multilevel population (SA 0.64% vs SC 0.33%,  $P < .01$ ), but in contrast to previous studies.<sup>24</sup> This finding must be interpreted cautiously as our study design precludes control for factors that influence dysphagia such as surgical time, number of levels fused, and operative level, especially above C3.<sup>25,26</sup>

Given our finding of potentially higher one-year revision rates in ACDF with synthetic cages, we suggest further economic investigation of these devices, in parallel with clinical evaluation, is warranted. Limited data comparing the cost-effectiveness of ACDF with structural allograft or synthetic cage is currently available. Using a 10-year-Markov state transition model, Virk et al<sup>27</sup> found that PEEK cages had an incremental cost-effectiveness ratio over \$100 000/quality-adjusted life year gained compared with autograft or structural allograft, leading to the conclusion that the technique is not cost effective compared with these alternatives. Beyond the differences in implant costs—structural allograft has been cited to cost up to \$2552 and synthetic cages up to \$7928 per implant<sup>28</sup>—operative time, hospital length of stay, complication rates, and post-discharge resource utilization are important cost drivers that require further direct comparison.

Synthetic cages that widely exist on the market today are composed of PEEK, titanium alloys, and carbon fiber with numerous studies attesting for their efficacy in spinal fusion.<sup>29</sup> One systematic review assessing clinical and radiographic outcomes of synthetic cages in ACDF found no differences in outcomes between PEEK, titanium, and carbon fiber cages, but titanium and carbon fiber cages were correlated with increased cost and higher subsidence rate in comparison to PEEK cages.<sup>30</sup> Given its radiolucency, low elastic modulus resulting in stress shielding, and similarities to cancellous bone, PEEK has been more widely used as an implant material for spinal fusion.<sup>11,29,31</sup> However, PEEK has been demonstrated to have a hydrophobic surface preventing protein absorption and promotion of cell adhesion interfering host-bone integration by the formation of an encapsulating fibrous layer.<sup>32,33</sup> While coating PEEK with a bioactive substance such as titanium has shown to

be effective in improving its biocompatibility, it is also associated with biological and inflammatory reactions in human and animal studies.<sup>34</sup> In addition to these drawbacks, fusion mass may not form in the space occupied by the synthetic cage with less endplate surface area and intervertebral volume available, as hypothesized in Pirkle et al<sup>18</sup> study. On the contrary, allograft possess osteoinductive properties and provides osteoconductive scaffold for new bone formation with relatively high fusion rates comparable to autografts, especially with plating techniques.<sup>29,35</sup> In addition to implant material, the use of an anterior plate and the type of nonstructural biologic material used in conjunction with a synthetic cage are other important aspects of the surgical procedure that influence postoperative outcomes. In a meta-analysis of 19 studies, patients who underwent ACDF with a cage-only technique had significantly lower rates of postoperative dysphagia and adjacent segment disease compared with patients who underwent ACDF with a cage-plate technique, but the cage-plate technique had better radiographic outcomes with significantly less subsidence and better restoration of cervical lordosis. No other significant differences in outcomes or postoperative complications were observed.<sup>36</sup> The choice of nonstructural biologic graft for use with synthetic cages is considered an important factor that influences postoperative fusion rates, but surgeons report there is insufficient comparative data to help select between grafts.<sup>11</sup> Due to small sample sizes and potential for bias, much of the evidence regarding biologic selection is of limited quality, making this an important area of future research.<sup>37</sup> Given the complex interaction between multiple factors that influence ACDF success, our findings are unable to pinpoint a precise reason for the trends observed and highlight the need for a prospective randomized controlled trial comparing structural allograft and synthetic cages before adequate evidence supporting the superiority of either implant is generated.

The analysis of any administrative database comes with several limitations. First, the TriNetX database relies heavily on coded data from multiple institutions yet this data carries the potential lack of fidelity associated with coding and may not be a representative sample of all patients undergoing ACDF surgery. Second, using coded data we were unable to differentiate between various implant materials, important aspects of the surgical procedure performed (such as the type of biologic used in conjunction with a synthetic cage or whether a plate was used), or the number of levels involved in multilevel procedures. The inability to differentiate between the number of segments involved in multilevel fusions is a significant limitation, as previous studies have identified multilevel surgeries as a risk factor for revision,<sup>22,23,38,39</sup> and a 27% increased risk of revision has been reported for 3 or more level compared with 2-level ACDF.<sup>23</sup> Third, our data set did not allow for specification of the diagnosis associated with revision surgery, and therefore limits our ability to infer the reason for revision. This is especially important in the context of the postoperative pseudoarthrosis rates presented, as these may or may not have been symptomatic or required further intervention. Fourth, while we

feel that the use of propensity score matching provides valuable control for confounding factors that may influence outcomes after surgery, the inherent limitations of observational studies and potential influence of unmeasured confounding covariates remains.

While few studies have directly compared complications and outcomes of structural allografts and synthetic cages, our findings further contribute to a growing body of literature that highlights the apparent increased risk of revision surgery following ACDF with synthetic cages compared with structural allograft bone. Despite the widespread use of synthetic cages, further large-scale, prospective studies that include parallel cost-effectiveness analysis are needed to determine if there are additional clinical benefits that outweigh the additional cost and potential increased risk of complications, including revision surgery.

## Conclusion

Compared with structural allograft, patients undergoing multi-level ACDF with synthetic cage may be at increased risk for 1-year revision surgery, while those receiving structural allograft may be at increased risk for dysphagia. No differences in post-operative complication rates between implants were observed in single-level ACDF. Further large-scale, prospective comparison of structural allografts and synthetic cages for ACDF is warranted before the superiority of either implant can be concluded.



## Declaration of Conflicting Interests

The author(s) declared no potential conflicts of interest with respect to the research, authorship, and/or publication of this article.

## Funding

The author(s) received no financial support for the research, authorship, and/or publication of this article.

## ORCID iD

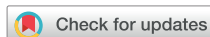Nandakumar Menon, MD  <https://orcid.org/0000-0002-0363-1532>  
Chad Patton, MD, MSc  <https://orcid.org/0000-0002-0911-8051>

## References

1. Marawar S, Girardi FP, Sama AA, et al. National trends in anterior cervical fusion procedures. *Spine (Phila Pa 1976)*. 2010;35:1454-1459. doi:10.1097/BRS.0b013e3181bef3cb
2. Saifi C, Fein AW, Cazzulino A, et al. Trends in resource utilization and rate of cervical disc arthroplasty and anterior cervical discectomy and fusion throughout the United States from 2006 to 2013. *Spine J*. 2018;18:1022-1029. doi:10.1016/j.spinee.2017.10.072
3. Cloward RB. The anterior approach for removal of ruptured cervical disks. *J Neurosurg*. 1958;15:602-617. doi:10.3171/jns.1958.15.6.0602
4. RA R, Smith G. Anterolateral cervical disc removal and interbody fusion for cervical disc syndrome. *Bull Johns Hopkins Hosp*. 1955;96:223-224.
5. Chau AMT, Mobbs RJ. Bone graft substitutes in anterior cervical discectomy and fusion. *Eur Spine J*. 2009;18:449-464. doi:10.1007/s00586-008-0878-4
6. Bishop RC, Moore KA, Hadley MN. Anterior cervical interbody fusion using autogeneic and allogeneic bone graft substrate: a prospective comparative analysis. *J Neurosurg*. 1996;85:206-210. doi:10.3171/jns.1996.85.2.0206
7. Jacobs W, Willems PC, Kruijt M, et al. Systematic review of anterior interbody fusion techniques for single- and double-level cervical degenerative disc disease. *Spine (Phila Pa 1976)*. 2011;36:E950-E960. doi:10.1097/BRS.0b013e31821cbba5
8. Kim DH, Rhim R, Li L, et al. Prospective study of iliac crest bone graft harvest site pain and morbidity. *Spine J*. 2009;9:886-892. doi:10.1016/j.spinee.2009.05.006
9. Silber JS, Anderson DG, Daffner SD, et al. Donor site morbidity after anterior iliac crest bone harvest for single-level anterior cervical discectomy and fusion. *Spine (Phila Pa 1976)*. 2003;28:134-139. doi:10.1097/00007632-200301150-00008
10. Maharaj MM, Phan K, Mobbs RJ. Anterior cervical discectomy and fusion (ACDF) autograft versus graft substitutes: what do patients prefer? A clinical study. *J Spine Surg*. 2016;2:105-110. doi:10.21037/jss.2016.05.01
11. Yoon ST, Konopka JA, Wang JC, et al. ACDF graft selection by surgeons: survey of AOSpine Members. *Global Spine J*. 2017;7:410-416. doi:10.1177/2192568217699200
12. McGuire KJ, Harrast J, Herkowitz H, Weinstein JN. Geographic variation in the surgical treatment of degenerative cervical disc disease: American Board of Orthopedic Surgery Quality Improvement Initiative; part II candidates. *Spine (Phila Pa 1976)*. 2012;37:57-66. doi:10.1097/BRS.0b013e318212bb61
13. Miller LE, Block JE. Safety and effectiveness of bone allografts in anterior cervical discectomy and fusion surgery. *Spine (Phila Pa 1976)*. 2011;36:2045-2050. doi:10.1097/BRS.0b013e3181ff37eb
14. Pereira EAC, Chari A, Hempenstall J, Leach JCD, Chandran H, Cadoux-Hudson TAD. Anterior cervical discectomy plus intervertebral polyetheretherketone cage fusion over three and four levels without plating is safe and effective long-term. *J Clin Neurosci*. 2013;20:1250-1255. doi:10.1016/j.jocn.2012.10.028
15. Wewel JT, Kasliwal MK, Adogwa O, Deutsch H, O'Toole JE, Traynelis VC. Fusion rate following three- and four-level ACDF using allograft and segmental instrumentation: A radiographic study. *J Clin Neurosci*. 2019;62:142-146. doi:10.1016/j.jocn.2018.11.040
16. Krause KL, Obayashi JT, Bridges KJ, Raslan AM, Than KD. Fivefold higher rate of pseudarthrosis with polyetheretherketone interbody device than with structural allograft used for 1-level anterior cervical discectomy and fusion. *J Neurosurg Spine*. 2019;30:46-51. doi:10.3171/2018.7.SPINE18531
17. Goz V, Buser Z, D'Oro A, et al. Complications and risk factors using structural allograft versus synthetic cage: analysis 17783 anterior cervical discectomy and fusions using a national registry. *Global Spine J*. 2019;9:388-392. doi:10.1177/2192568218797096
18. Pirkle S, Kaskovich S, Cook DJ, Ho A, Shi LL, Lee MJ. Cages in ACDF are associated with a higher nonunion rate than allograft: a stratified comparative analysis of 6130 patients. *Spine (Phila Pa 1976)*. 2019;44:384-388. doi:10.1097/BRS.0000000000002854



19. TriNetX. TriNetX—answers at the speed of thought. Accessed June 29, 2020. <https://www.trinetx.com/page/4/#home-slider-3-copy>
20. Park HW, Lee JK, Moon SJ, Seo SK, Lee JH, Kim SH. The efficacy of the synthetic interbody cage and grafton for anterior cervical fusion. *Spine (Phila Pa 1976)*. 2009;34:E591-E595. doi:10.1097/BRS.0b013e3181ab8b9a
21. Lee DH, Cho JH, Hwang CJ, et al. What is the fate of pseudarthrosis detected 1 year after anterior cervical discectomy and fusion? *Spine (Phila Pa 1976)*. 2018;43:E23-E28. doi:10.1097/BRS.0000000000002077
22. Laratta JL, Reddy HP, Bratcher KR, McGraw KE, Carreon LY, Owens RK 2nd. Outcomes and revision rates following multilevel anterior cervical discectomy and fusion. *J Spine Surg*. 2018;4:496-500. doi:10.21037/jss.2018.06.16
23. Veeravagu A, Cole T, Jiang B, Ratliff JK. Revision rates and complication incidence in single- and multilevel anterior cervical discectomy and fusion procedures: an administrative database study. *Spine J*. 2014;14:1125-1131. doi:10.1016/j.spinee.2013.07.474
24. Gercek E, Arlet V, Delisle J, Marchesi D. Subsidence of stand-alone cervical cages in anterior interbody fusion: Warning. *Eur Spine J*. 2003;12:513-516. doi:10.1007/s00586-003-0539-6
25. Mehra S, Heineman TE, Cammisa FP Jr, Girardi FP, Sama AA, Kutler DI. Factors predictive of voice and swallowing outcomes after anterior approaches to the cervical spine. *Otolaryngol Head Neck Surg*. 2014;150:259-265. doi:10.1177/0194599813515414
26. Anderson KK, Arnold PM. Oropharyngeal dysphagia after anterior cervical spine surgery: a review. *Global Spine J*. 2013;3:273-286. doi:10.1055/s-0033-1354253
27. Virk SS, Elder JB, Sandhu HS, Khan SN. The cost effectiveness of polyetheretherketone (PEEK) cages for anterior cervical discectomy and fusion. *J Spinal Disord Tech*. 2015;28:E482-E492. doi:10.1097/BSD.0b013e3182aa3676
28. Epstein N. Iliac crest autograft versus alternative constructs for anterior cervical spine surgery: Pros, cons, and costs. *Surg Neurol Int*. 2012;3(suppl 3):S143-S156. doi:10.4103/2152-7806.98575
29. Pisano AJ, Short TK, Formby PM, Helgeson MD. Anterior cervical discectomy and fusion techniques: Bone graft, biologics, interbody spacers, and plating options. *Semin Spine Surg*. 2016;28:84-89. doi:10.1053/j.semss.2015.11.003
30. Kersten RFMR, Van Gaalen SM, De Gast A, Öner FC. Polyetheretherketone (PEEK) cages in cervical applications: a systematic review. *Spine J*. 2015;15:1446-1460. doi:10.1016/j.spinee.2013.08.030
31. Hee HT, Kundnani V. Rationale for use of polyetheretherketone polymer interbody cage device in cervical spine surgery. *Spine J*. 2010;10:66-69. doi:10.1016/j.spinee.2009.10.014
32. Noiset O, Schneider YJ, Marchand-Brynaert J. Fibronectin adsorption or/and covalent grafting on chemically modified PEEK film surfaces. *J Biomater Sci Polym Ed*. 1999;10:657-677. doi:10.1163/156856299X00865
33. Toth JM, Wang M, Estes BT, Scifert JL, Seim HB, Turner AS. Polyetheretherketone as a biomaterial for spinal applications. *Biomaterials*. 2006;27:324-334. doi:10.1016/j.biomaterials.2005.07.011
34. McGilvray KC, Easley J, Seim HB, et al. Bony ingrowth potential of 3D-printed porous titanium alloy: a direct comparison of interbody cage materials in an in vivo ovine lumbar fusion model. *Spine J*. 2018;18:1250-1260. doi:10.1016/j.spinee.2018.02.018
35. Yue J, Guyer R, Johnson JP, Khoo L, Hochschuler S. *The Comprehensive Treatment of the Aging Spine*. 1st ed. Elsevier; 2011. doi:10.1016/C2009-0-39568-9
36. Cheung ZB, Gidumal S, White S, et al. Comparison of anterior cervical discectomy and fusion with a stand-alone interbody cage versus a conventional cage-plate technique: a systematic review and meta-analysis. *Global Spine J*. 2019;9:446-455. doi:10.1177/2192568218774576
37. Buser Z, Brodke DS, Youssef JA, et al. Synthetic bone graft versus autograft or allograft for spinal fusion: a systematic review. *J Neurosurg Spine*. 2016;25:509-516. doi:10.3171/2016.1.SPINE151005
38. Wang M, Chou D, Chang CC, et al. Anterior cervical discectomy and fusion performed using structural allograft or polyetheretherketone: pseudarthrosis and revision surgery rates with minimum 2-year follow-up. *J Neurosurg Spine*. [published online December 13, 2019]. doi:10.3171/2019.9.SPINE19879
39. Epstein NE. A review of complication rates for anterior cervical discectomy and fusion (ACDF). *Surg Neurol Int*. 2019;10:100. doi:10.25259/sni-191-2019



# Structural Allograft versus Polyetheretherketone Implants in Patients Undergoing Spinal Fusion Surgery: A Systematic Review and Meta-Analysis

Nida Fatima, Elie Massaad, Ganesh M. Shankar, John H. Shin

## Key words

- Allograft
- Fusion
- PEEK implant
- Spinal fusion surgery
- Subsidence

## Abbreviations and Acronyms

CI: Confidence interval

OR: Odds ratio

PEEK: Polyetheretherketone

Department of Neurosurgery, Massachusetts General Hospital, Harvard Medical School, Boston, Massachusetts, USA

To whom correspondence should be addressed:  
Nida Fatima, M.B.B.S., M.D.

[E-mail: [nfatima@mgh.harvard.edu](mailto:nfatima@mgh.harvard.edu)]

Citation: *World Neurosurg.* (2020) 136:101–109.  
<https://doi.org/10.1016/j.wneu.2020.01.006>

Journal homepage: [www.journals.elsevier.com/world-neurosurgery](http://www.journals.elsevier.com/world-neurosurgery)

Available online: [www.sciencedirect.com](http://www.sciencedirect.com)

1878-8750/\$ - see front matter © 2020 Elsevier Inc. All rights reserved.

## INTRODUCTION

The evolution of interbody spacers has revolutionized spinal fusion surgery, as these spacers restore disc height, provide stability, and promote bony fusion.<sup>1</sup> With comparable elastic modulus values and mechanical properties similar to autologous bone, structural bone allograft and polyetheretherketone (PEEK) synthetic cages have gained immense popularity over other alternatives, such as autograft.<sup>2</sup> The osteoconductive scaffold demonstrating osseointegration in a rat model by structural allograft has shown a long history of successful clinical use.<sup>3</sup> However, in vivo models of PEEK implants demonstrate lack of osseointegration as well as the growth of fibrous tissue.<sup>4,5</sup> Therefore, modifications of surface enhancement through titanium coating, increased surface porosity, and impregnation of PEEK with bioactive materials such as hydroxyapatite have

■ **OBJECTIVE:** Interbody spacers have been successfully used in spinal fusion procedures with the aim to restore disc height, provide stability, and promote bone fusion. The authors evaluated the efficacy of structural body allograft versus polyetheretherketone (PEEK) implants in patients undergoing spinal fusion surgery.

■ **METHODS:** A systematic review of electronic databases was conducted using different Medical Subject Headings terms from January 1970 to August 2019. Pooled and subgroup analyses were performed using random-effects and fixed-effects models based on  $I^2$  heterogeneity.

■ **RESULTS:** The analysis included 6640 patients (structural allograft 64% and PEEK cage 36%) from 7 comparative studies. There were no statistically significant differences in age ( $P = 0.27$ ), sex ( $P = 0.31$ ), body mass index ( $P = 0.82$ ), and smoking status ( $P = 0.27$ ) between the 2 groups. Overall, the mean follow-up was  $12.9 \pm 1.5$  months. Pooled meta-analysis revealed that patients with structural allograft had 2.59-fold higher likelihood of fusion compared with patients with PEEK cages (odds ratio [OR] 2.59, 95% confidence interval [CI] 1.02–6.57,  $P = 0.05$ ) at last follow-up evaluation. Patients with structural allograft had 61% less likelihood of pseudarthrosis (OR 0.39, 95% CI 0.15–0.98,  $P = 0.05$ ) and 74% lower incidence of reoperation compared with patients with PEEK implants (OR 0.26, 95% CI 0.09–0.79,  $P = 0.02$ ). Our results suggest that patients with structural allografts had a higher subsidence rate compared with patients with PEEK implants, but this was statistically insignificant (OR 1.07, 95% CI 0.45–2.53,  $P = 0.89$ ).

■ **CONCLUSIONS:** Our results corroborate that structural allografts are highly effective in promoting bony fusion compared with PEEK implants in patients undergoing spinal fusion surgery.

been proposed.<sup>6</sup> Although the restoration and maintenance of disc space height are the main goals of fusion surgeries, literature exists regarding the failure of mechanical function in supporting the anterior column through bone graft while assuming an essential biologic role to promote bone growth.<sup>7,8</sup> Nonetheless, there is insufficient evidence supporting the use of structural allograft over PEEK implants in spinal fusion procedures. To evaluate the differences between these spacers, we conducted a systematic review and meta-analysis of all available literature comparing structural body allograft and PEEK implants in spinal fusion

surgery and associated surgical and radiographic outcomes, including subsidence, pseudarthrosis, fusion rate, reoperation, and patient-reported outcomes.

## MATERIALS AND METHODS

### Data Source and Search Strategy

We conducted a literature search according to the guidelines provided by the Preferred Reporting Items for Systematic Review and Meta-Analysis.<sup>9</sup> Two reviewers (N.F. and J.H.S.) conducted a detailed systematic review of electronic databases (PubMed, Embase, Scopus, Medline, and

Google Scholar) for articles published between January 1990 and November 2019. We used different Medical Subject Headings terms (with Boolean operators “AND” and “OR”) including “allograft,” “structural body allograft,” “polyetheretherketone,” “PEEK,” “femoral cortical allograft,” “femoral ring allograft,” “cage,” “cervical fusion,” “lumbar fusion,” and “interbody fusion.” We included only articles that were published in English.

### Eligibility Criteria

Eligible studies were of spinal fusion procedures that compared structural allograft and PEEK cages for primary diagnoses of degenerative spinal disease, trauma, herniated disc, and ossified posterior longitudinal ligament. We included only studies that reported at least 1 of the following clinical or radiographic outcomes: subsidence, pseudarthrosis, fusion rate, or patient-reported outcomes. Exclusion criteria were case reports, case series, and implantation of the cage in the setting of spinal infection.

### Data Extraction and Outcome Measures

The data were extracted by 2 authors (N.F. and J.H.S.) using a structured template form based on Cochrane Consumers and Communication Group. Any disagreement between the 2 authors was resolved by discussion. The following data were extracted from each article: 1) demographic characteristics of each cohort, 2) clinical conditions, 3) intraoperative parameters (surgical approaches and number of levels involved), 4) type of allograft used during each study, and 5) outcome parameters (subsidence rate, mean change in lordotic angle, pseudarthrosis, reoperation, fusion rates, and patient-reported outcome measures).

### Evidence Quality Assessment

The Grades of Recommendation, Assessment, Development and Evaluation protocol<sup>10</sup> was used to assess the quality of evidence for each study independently by the 2 reviewers. Each study was given an overall rating based on study design, limitations, and results as high, moderate, low, or very low.

### Statistical Analysis

RevMan 5.3 (The Nordic Cochrane Centre, The Cochrane Collaboration, Copenhagen, Denmark) was used for comparing data from the included studies. Dichotomous data were reported as odds ratio (OR) with 95% confidence interval (CI). Heterogeneity among studies was evaluated using  $I^2$  statistics. A fixed-effects model was used for  $I^2 < 50\%$ , and a random-effects model was used for  $I^2 \geq 50\%$ . All tests were 2-tailed, and  $P < 0.05$  was considered as statistically significant. Subsidence was defined as decrease in anterior and/or posterior disc heights by  $>2$  mm. Radiographic fusion was defined as presence of bridging bone in front of or through the radiolucent cage or allograft incorporation into the surrounding bone. IBM SPSS Version 25 software (IBM Corporation, Armonk, New York, USA) was used to evaluate for differences between groups using independent sample t tests, and  $\chi^2$  statistical analysis was used for assessment of categorical variables.

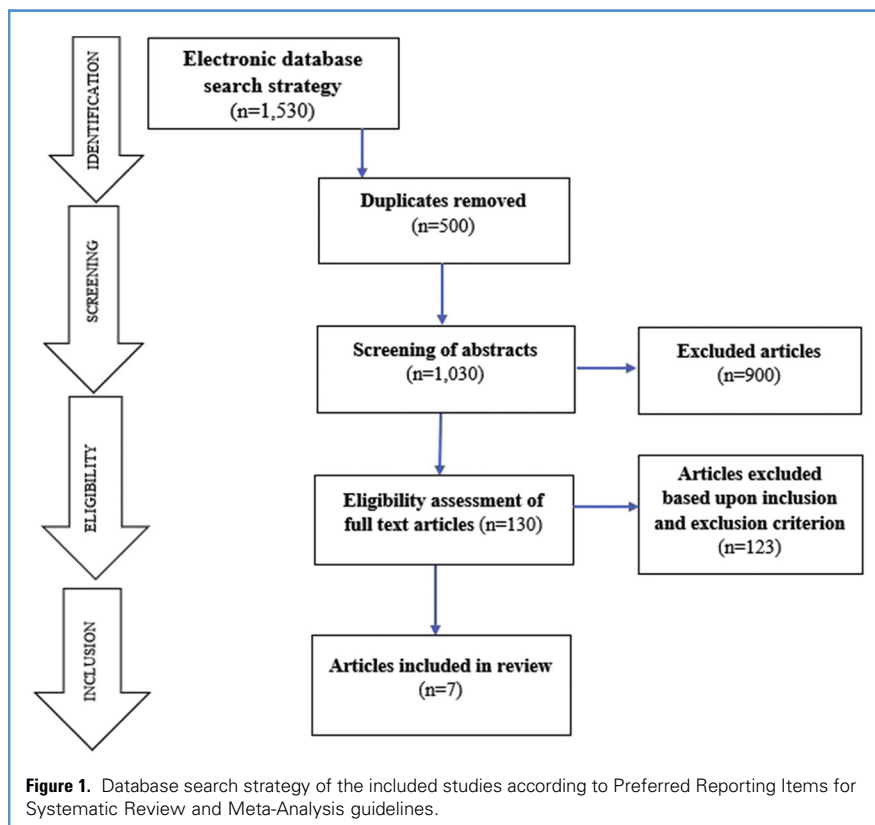
### Risk of Bias Across Studies

No randomized controlled trials were included in our analysis. Furthermore, double blindness was not achieved in any study. The high heterogeneity among studies was further analyzed using funnel plots, which showed the asymmetric distribution. This bias can be attributable to the sample size, as the removal of the smaller sized cohort significantly decreased the heterogeneity.

## RESULTS

### Literature Search

A flow diagram in accordance with the Preferred Reporting Items for Systematic Review and Meta-Analysis guidelines<sup>9</sup> was plotted as shown in Figure 1. The reviewers retrieved 1530 articles from PubMed, Embase, Scopus, Medline, and Google Scholar. Of 1530 articles, 500 articles were removed owing to duplication in different electronic databases, and a further 900 articles were excluded because of data not related to spinal fusion surgery. Lastly, 123 of the remaining 130 articles were excluded owing to lack of quantitative data and absence of comparison groups.



**Table 1.** Baseline Characteristics of Included Studies

Reference	Type of Study	Levels	Patients (N)	Case/Control*	F/M Sex	Mean Age (years)	BMI	Smokers	Mean FU (months)	Type of Surgery	Type of Allograft	Indications of Surgery
Cutler et al., 2006 <sup>8</sup>	Retro	Single-level	39	21 (53.8)/18 (46.2)	12 (57)/9 (23): 10 (55.5)/8 (20.5)	45.8/50.2	NA	4 (19)/5 (27.7)	15.1	TLIF	Femoral cortical bone allograft	DDD: 27; recurrent disc herniation: 7; grade I or II degenerative spondylolisthesis: 5
Wan et al., 2014 <sup>11</sup>	Retro	Multilevel	48 (83)	30 (36.1)/53 (63.8)	38 (79.2)/10 (20.8)	56.3	24.3	1 (2.1)	12	ALIF	Femoral ring allografts	Spine deformities including scoliosis, kyphosis and flat-back syndrome
Yson et al., 2017 <sup>12</sup>	Retro	Multilevel	67 (117)	19 (32)/48 (85)	12 (63.2)/7 (36.8): 27 (56.3)/21 (43.7)	48.6/52.5	NA	NA	14.7	ACDF	Structural fibular allograft	Herniated nucleus pulposus: 24; multilevel cervical spondylosis: 24; foraminal stenosis: 7, adjacent segment disease: 5; myelopathy: 4; degenerative spondylolisthesis: 2; DDD: 1
Pirkle et al., 2019 <sup>13</sup>	Retro†	Multilevel	6130	4063 (66)/2067 (34)	NA	NA	NA	60/2195 (2.7)/69/1034 (6.7)	12	ACDF	Structural allograft	NA
Teton et al., 2019 <sup>14</sup>	Retro	Multilevel	62	31 (50)/31 (50)	NA	NA	NA	NA	NA	ACDF	Structural allograft	NA
Hill et al., 2019 <sup>15</sup>	Retro	Multilevel	167	39 (23.4)/128 (76.6)	22 (56.4)/17 (43.6): 75 (58.6)/53 (41.4)	53.8/55.0	31.0/29.9	8 (20.5)/12 (9.4)	12	ACDF	Structural allograft	DDD and cervical trauma
Krause et al., 2019 <sup>16</sup>	Retro	Single-level	127	71 (55.9)/56 (44.1)	37 (52.1)/34 (47.8): 35 (62.5)/21 (37.5)	53/51	28.4/29.1	17 (23.9)/15 (26.7)	16/21	ACDF	Structural allograft composed of composite, cortical, or cancellous materials	DDD and cervical trauma

Numbers in parentheses are percentages.

F, female; M, male; BMI, body mass index; FU, follow-up; Retro, retrospective; TLIF, transforaminal lumbar interbody fusion; DDD, degenerative disc disease; ALIF, anterior lumbar interbody fusion; NA, not available; ACDF, anterior cervical disc fusion.

\*Case: structural allograft; Control: polyetheretherketone cage.

†Pearl Driver National Database.

**Table 2.** Outcome Characteristics Including Clinical and Radiographic Factors of Included Studies

Reference	Subsidence Rate	Mean NDI Improvement	Mean Change in Lordotic Angle (°)	Pseudarthrosis	Reoperation	Fusion Rate
Cutler et al., 2006 <sup>8</sup>	2/21:0/18	ODI: 42.3/40.2	2.68/1.72	1/21: 0/18	1/21: 0/18	95.2%/100%
Wan et al., 2014 <sup>11</sup>	NA	NA	1.8 ± 1.7/2.5 ± 4.2	5/30: 3/53	NA	84.2%/94.9%
Yson et al., 2017 <sup>12</sup>	9/32:25/85	Subsidence: 7.1; nonsubsidence: 16.6	NA	1/19: 4/48	1/19: 4/48	94.7%/91.6%
Pirkle et al., 2019 <sup>13</sup>	NA	NA	NA	80/4063: 110/2067	NA	98.0%/94.7%
Teton et al., 2019 <sup>14</sup>	NA	NA	NA	6/31: 20/31	0/31: 4/31	81%/35%
Hill et al., 2019 <sup>15</sup>	NA	0.4/0.6	NA	NA	NA	NA
Krause et al., 2019 <sup>16</sup>	NA	NA	NA	7/71: 29/56	1/71: 7/56	90%/48.3%

NDI, Neck Disability Index; ODI, Oswestry Disability Index; NA, not available.

Hence, 7 comparative studies were included in our meta-analysis.<sup>8,11-16</sup>

### Study Characteristics

All studies were retrospective in nature. These studies were carried out in the United States ( $n = 6$ ), and China ( $n = 1$ ). The baseline characteristics, outcome characteristics, and comparison of both groups are presented in **Tables 1–3**.

Our analysis included 6640 patients; 4250 (64.0%) underwent procedures with structural allograft, and 2390 (36.0%) underwent procedures with PEEK cages. The mean follow-up in both groups was  $12.9 \pm 1.5$  months. The quality of evidence as assessed by the Grades of

Recommendation, Assessment, Development and Evaluation assessment was deemed very low in 4 studies and low in 3 studies.

Of the available data ( $n = 448$ ),  $\chi^2$  statistical analysis was performed to look at the comparative analysis of male versus female patients in structural allograft and PEEK cage groups, with 121 female and 77 male patients in the structural allograft group and 103 female and 147 male patients in the PEEK cage group. There was no statistically significant difference in gender distribution between the structural allograft group and PEEK group ( $P = 0.31$ ). Furthermore, the mean age (SD) for the structural allograft and PEEK groups

was 51.5 (4.3) and 53.0 (2.6), respectively. There was no statistically significant difference in age between the 2 groups ( $P = 0.27$ ).

The mean body mass index was  $27.9 \pm 3.4$  kg/m<sup>2</sup> among patients with structural allograft and  $27.8 \pm 3.1$  kg/m<sup>2</sup> among patients with PEEK cages. There was no statistically significant difference between the 2 cohorts ( $P = 0.82$ ). Similarly, there was no statistically significant difference in data related to smoking between the 2 groups ( $P = 0.27$ ).

### Operative Data

The spinal fusion surgeries in our meta-analysis included anterior cervical discectomy and fusion ( $n = 5$ ),<sup>12-16</sup> anterior lumbar interbody fusion ( $n = 1$ ),<sup>11</sup> and thoracolumbar interbody fusion ( $n = 1$ ).<sup>8</sup> Five studies<sup>11-15</sup> involved multilevel spinal fusion surgery, and 2 studies<sup>8,16</sup> involved single-level spinal fusion surgery. The structural allografts included femoral cortical bone allograft ( $n = 1$ ), femoral ring allograft ( $n = 1$ ), fibular allograft ( $n = 1$ ), and unspecified ( $n = 4$ ). Owing to the inclusion of 1 study with data from a national database,<sup>13</sup> there was moderate heterogeneity in terms of type and number of PEEK cages for comparative analysis. Data regarding estimated blood loss and operative time was scarce, and therefore analysis could not be performed.

### Postoperative Patient-Reported Outcomes

The study design revealed significant heterogeneity about patient-reported outcomes, and therefore clinically meaningful

**Table 3.** Demographic, Radiographic, and Clinical Characteristics of Included Studies Comparing the 2 Cohorts

Parameter	Structural Allograft	PEEK Cage	P Value
Number of patients	4250	2390	—
Sex, F/M*	121/77	103/147	0.31
Age, years, mean ± SD	51.5 ± 4.3	53.0 ± 2.6	0.27
BMI, kg/m <sup>2</sup> , mean ± SD	27.9 ± 3.4	27.8 ± 3.1	0.82
Smokers	90	102	0.27
Follow-up, months, mean ± SD	12.9 ± 1.5	12.9 ± 1.5	—
Pseudarthrosis	120	213	0.02†
Reoperation	3	15	0.13
Fusion rate, mean ± SD	90.5 ± 6.7	77.4 ± 28.2	0.24

PEEK, polyetheretherketone; F, female; M, male; BMI, body mass index.

\*Sample size is smaller than the total number of patients owing to lack of data provided in the included studies.

†Statistically significant.



**Table 4.** Patient-Reported Outcome Characteristics of Included Studies

Reference	Mean NDI Improvement	Neck VAS	Arm VAS	Mean ODI Improvement	Mean Prolo Scale Improvement
Cutler et al., 2006 <sup>8</sup>	—	—	—	42.3/40.2	—
Wan et al., 2014 <sup>11</sup>	—	—	—	—	3.1 ± 1.1/3.5 ± 0.8
Yson et al., 2017 <sup>12</sup>	7.1/16.6*	1.8/2.8*	5.9/1.6*	—	—
Pirkle et al., 2019 <sup>13</sup>	—	—	—	—	—
Teton et al., 2019 <sup>14</sup>	—	—	—	—	—
Hill et al., 2019 <sup>15</sup>	0.4/0.6	—	—	—	—
Krause et al., 2019 <sup>16</sup>	—	—	—	—	—

NDI, Neck Disability Index; VAS, visual analog scale; ODI, Oswestry Disability Index.  
\*Subsidence/nonsubsidence.

statistical analysis could not be performed. However, none of the included studies reported a significant difference between the 2 groups in Neck Disability Index, visual analog scale, Oswestry Disability Index, and Prolo Scale. Patient-reported outcome characteristics of the included studies are presented in **Table 4**.

### Radiologic Outcome

**Fusion Rate.** The fusion rate at the last follow-up was 81%–98% (pooled proportion: 90.5%) in patients with structural allograft compared with 35%–100% in patients with PEEK cages (pooled proportion: 77.4%). The pooled meta-analysis revealed that patients with structural allograft had 2.59-fold higher likelihood of fusion compared with patients with PEEK cages (OR 2.59, 95% CI 1.02–6.57,  $P = 0.05$ ) at the last follow-up evaluation (**Figure 2**). Furthermore, patients with

structural allograft had 61% less likelihood of pseudarthrosis compared with patients with PEEK cages (OR 0.39, 95% CI 0.15–0.98,  $P = 0.05$ ) (**Figure 3**). Hence patients with structural allograft had 74% less likelihood of reoperation compared with patients with PEEK cages (OR 0.26, 95% CI 0.09–0.79,  $P = 0.02$ ) (**Figure 4**).

**Subsidence.** Only 2 studies<sup>8,12</sup> had sufficient data related to subsidence. There was no statistically significant difference in terms of subsidence between the study cohorts with structural allograft and PEEK cages (OR 1.07, 95% CI 0.45–2.53,  $I^2 = 0\%$ ,  $P = 0.89$ ) (**Figure 5**).

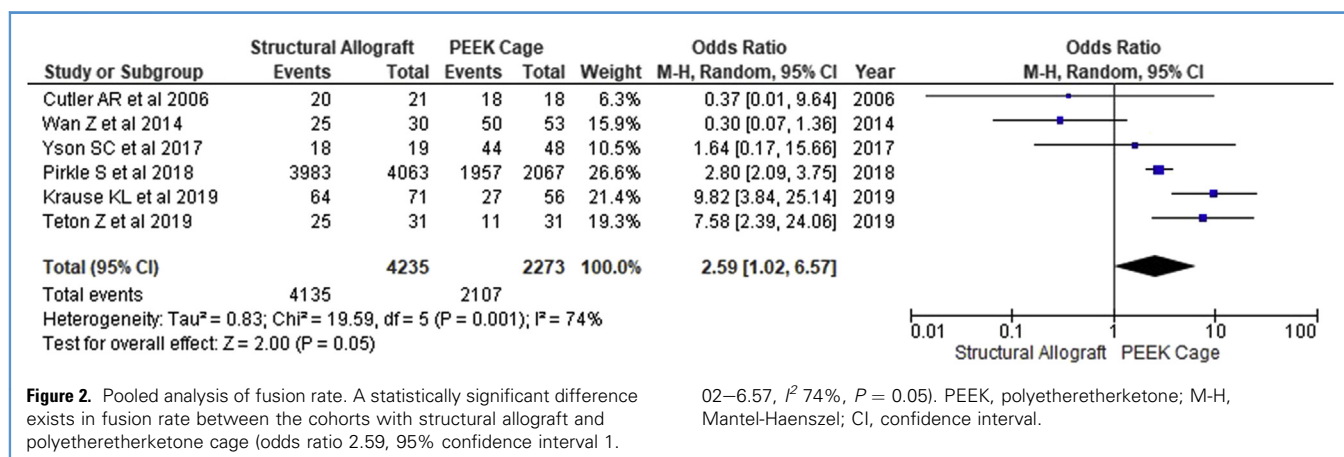
**Subgroup Analysis Based on Location.** Subgroup analysis to determine the fusion rate based on the spinal location was performed. Four included studies<sup>12–14,16</sup>

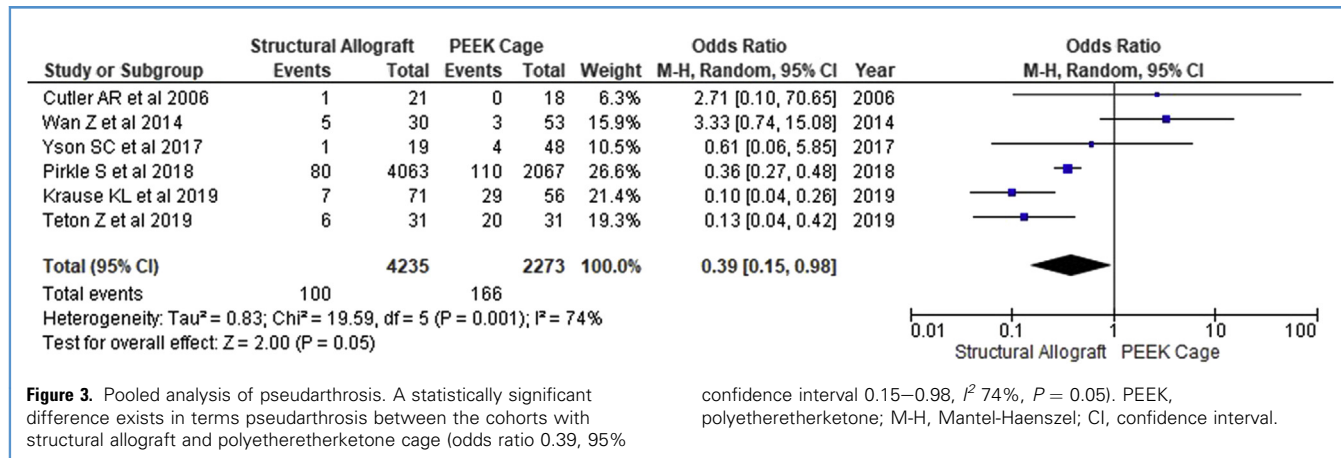
reported the comparative fusion rates in the cervical spine region, and 2 studies reported fusion rates in the lumbar spine area.<sup>8,11</sup> Our results corroborated the reported rates for the cervical spine region; the patients with structural allograft had 4.68-fold higher likelihood of fusion compared with the patients with PEEK cages (OR 4.68, 95% CI 2.08–10.54,  $P = 0.0002$ ) (**Figure 6A**). In contrast, the patients with structural allograft in the lumbar spine region had 69% less likelihood of fusion at the last follow-up than the patients with PEEK cages. This was borderline statistically significant (OR 0.31, 95% CI 0.08–1.22,  $P = 0.09$ ) (**Figure 6B**).

### DISCUSSION

This meta-analysis sought to determine 2 important outcome parameters associated with interbody spacers during spinal fusion surgery: 1) subsidence and fusion rate through radiographic evaluation, and 2) patient-reported outcomes. Furthermore, we did a comparative analysis of preoperative demographic parameters including age, sex, body mass index, and smoking status between the 2 groups.

This review included 6640 patients from 7 comparative studies. Most of the patients had structural allograft during spinal fusion surgery ( $n = 4250$ ; 64%), while the remaining patients ( $n = 2390$ ; 36%) had PEEK implants. The studies included in our meta-analysis involved interbody spacers following anterior cervical discectomy and fusion ( $n = 5$ ), anterior lumbar interbody fusion ( $n = 1$ ), and





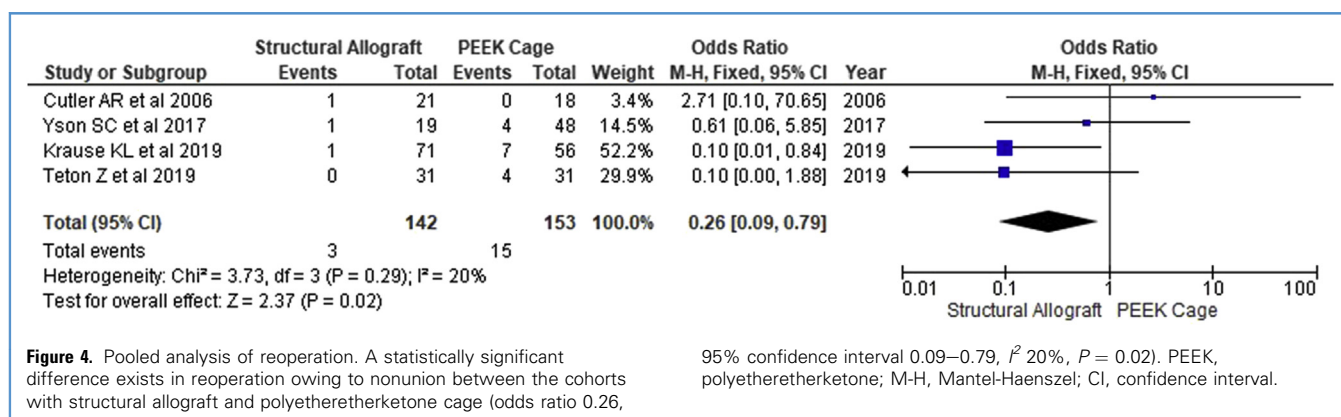
transforaminal lumbar interbody fusion ( $n = 1$ ) for degenerative disc disease and trauma. Degenerative disc disease and trauma are the most common diagnoses for patients experiencing neck and back pain.<sup>2,17</sup> These patients usually present with radiculopathic and myelopathic symptoms following compression of the nerve roots and spinal cord, respectively. The spinal fusion procedure involves removing the affected disc, excising the osteophytes, and decompressing the nerve root or spinal cord.<sup>2</sup> The residual disc space is implanted with a bone or synthetic graft for preservation and maintenance of the vertebral space height, with or without the additional support of plates and screws.<sup>2</sup>

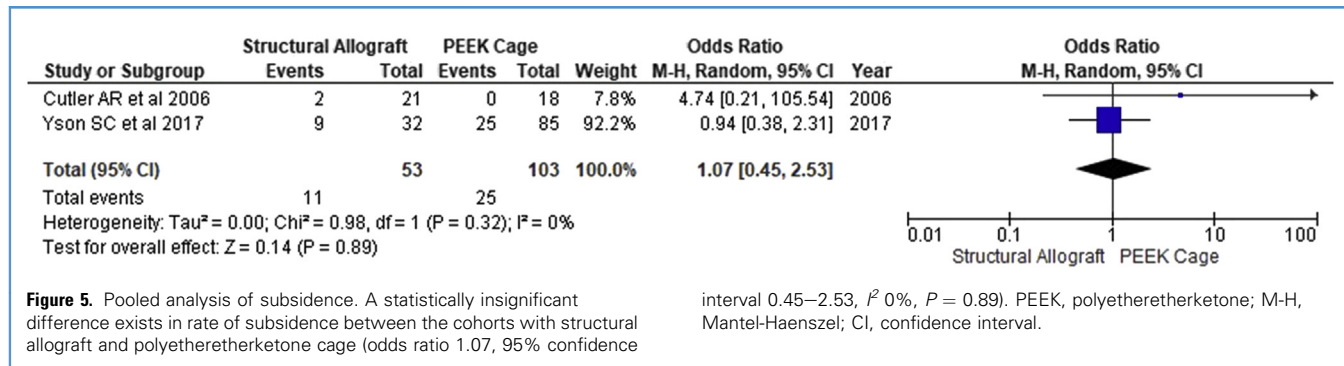
Following interbody spacer placement, the fusion rate is a key determinant of success.<sup>12</sup> However, a standardized criterion for fusion assessment does not exist.<sup>2</sup> In our review, most of the surgeons subjectively assessed fusion

through bridging trabecular bone and the absence of a radiolucent gap between endplates. Pooling results from our studies revealed that fusion rate was higher among patients with structural allograft by 2.59-fold compared with patients with PEEK implants ( $P = 0.05$ ). Thus, there was 61% less likelihood of pseudarthrosis ( $P < 0.05$ ) and 76% lower risk of reoperation among patients with structural allograft compared with patients with PEEK implants. PEEK is a nonabsorbable, semicrystalline polymer with elastic modulus similar to native bone (3.84 GPa). However, its inert nature and low surface energy affect the body's biologic response. Furthermore, the hydrophobic nature of PEEK potentially limits the protein-surface and cell-surface interactions, which eventually limit the cellular adhesions. In contrast, the structural allograft provides an osteoconductive scaffold for neovascularization and osseointegration and thus performs better.

Hence PEEK is associated with lower fusion rates regardless of providing excellent mechanical stability. The modifications to improve PEEK bioactivity in terms of surface coating with synthetic osteoconductive material, increasing the surface porosity and roughness through chemical modifications, and incorporating bioactive particles have gained widespread popularity.<sup>2,18,19</sup> However, our review did not control for these variations owing to lack of high-quality evidence comparing these modifications.

The patients with structural allograft had significantly better fusion rates in the cervical region (OR 4.68, 95% CI 2.08–10.54,  $P = 0.0002$ ) compared with patients with PEEK cages in the lumbar region (OR 0.31, 95% CI 0.08–1.22,  $P = 0.09$ ). This could be explained by the fact that the strong polymer material of the PEEK cage is able to withstand the compressive load of the vertebral column in the lumbar region, thus offering a higher fusion rate





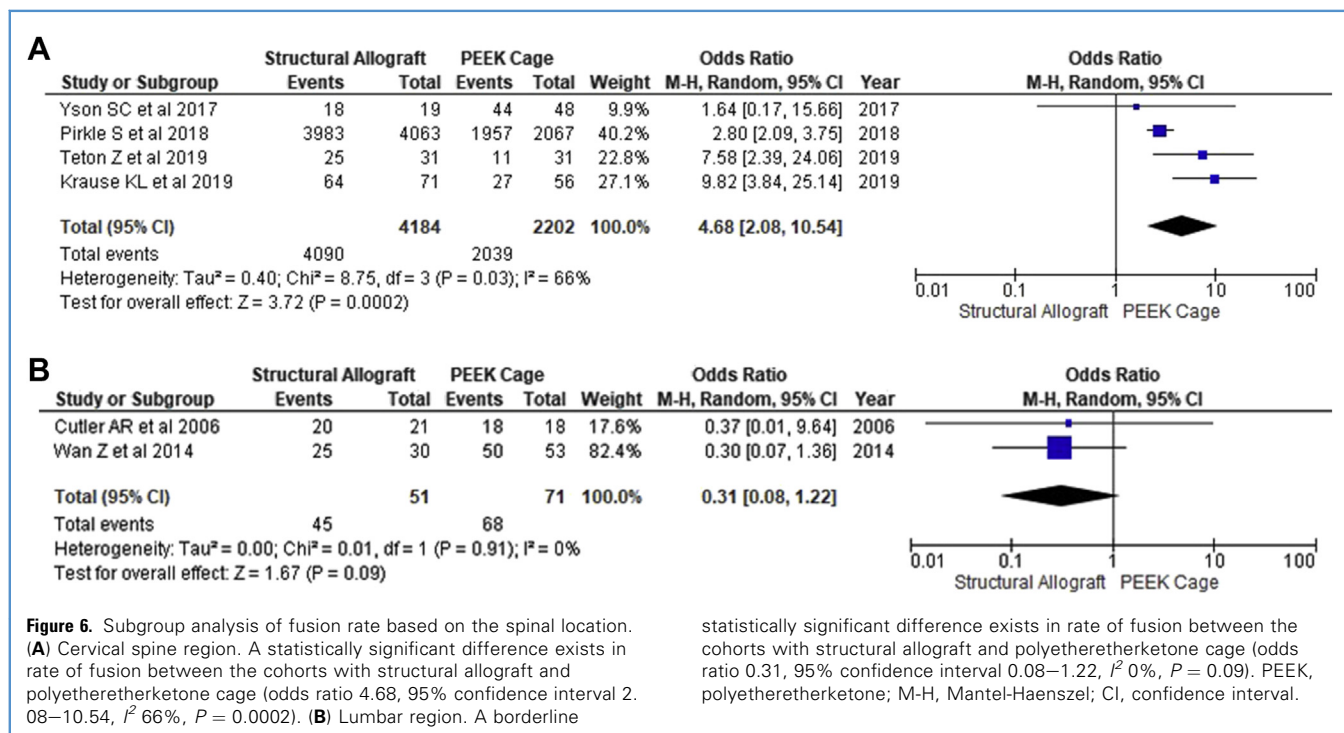
compared with structural allograft.<sup>8</sup> On the contrary, some studies suggest that the fusion rate is less with the PEEK cage in the cervical region, as it represents a mechanical block for fusion formation.<sup>13</sup> Furthermore, the PEEK cage provides less endplate surface area and less available intervertebral volume for arthrodesis, which is the possible cause of the lower fusion rate compared with the structural allograft.<sup>13</sup>

The mean radiographic follow-up after fusion in our included studies was  $12.9 \pm 1.5$  months. All included studies reported the fusion based on plain x-ray. In general, spinal arthrodesis takes at least 3 months to 1 year to achieve a solid fusion; hence it

is appropriate to repeat a plain x-ray after 1 year to determine the fusion rate.<sup>20</sup> However, in the assessment of patients who have undergone spinal arthrodesis, the clinical picture along with radiographic assessment should be considered for the further management plan.<sup>21</sup> The sensitivity and specificity of predicting the fusion rate with a plain radiograph were reported in the literature as 80% and 60%, respectively.<sup>22</sup> A few studies<sup>23,24</sup> have reported a lower fusion rate on computed tomography scans than on dynamic radiographs following spinal fusion procedures, whereas others have reported an equivalent fusion rate with computed tomography scan and plain

dynamic radiographs with a positive predictive value of 100% and negative predictive value of 85%.<sup>25</sup>

Furthermore, our meta-analysis revealed that the subsidence rate was 1.07-fold higher among patients with structural allograft compared with patients with PEEK implants. Although the results of our pooled analysis related to subsidence were statistically insignificant ( $P = 0.89$ ) owing to small sample sizes and lack of studies with high-quality evidence, our analysis highlights an important finding. As the structural bone allograft has an essential biologic role to promote bone growth, the disc height is mostly lost to achieve osseous fusion.<sup>8</sup>



Thus, allografts are associated with more postoperative disc height loss compared with PEEK cages. This is further strengthened by McAfee et al.,<sup>26</sup> who reported a 66% increase in intraoperative disc space height at 2-year follow-up in patients who underwent transforaminal lumbar interbody fusion using PEEK cages.<sup>26</sup> However, further studies are needed to compare the subsidence rates between structural allograft and PEEK implants in patients following spinal fusion surgery.

Patient-reported outcomes were described in only 4 studies<sup>8,11,12,15</sup> suggesting that these clinical outcomes are often not the focus of the studies. The scales for outcome assessment were different among these studies and included Neck Disability Index, visual analog scale, Oswestry Disability Index, and Prolo Scale, and a comparative analysis could not be performed. Tracking surgical outcomes, including the patient-reported outcome, is pivotal to understanding the clinical progress and has been in increasing use in clinical practice. However, variability exists in determining the clinical outcomes through these patient-reported outcome measures in spine surgery because they depend exclusively on the patient's response. This is acknowledged by Nayak et al.,<sup>27</sup> who reported the limitation in comparison of clinical outcomes in spine surgery research owing to variability in patient-reported outcome measures. In addition, although the subsidence rate after spinal fusion procedures has been well studied, the effects of subsidence on the clinical outcomes and fusion rate remain unclear.<sup>28</sup> Further studies are needed to determine the reliability, validity, and responsiveness of these patient-reported outcome measures.

In addition to the surgical effectiveness, structural allografts are cost-effective compared with PEEK cages in spinal fusion surgeries. Our included studies did not report the cost data; however, it is of paramount importance to highlight the cost savings of these spinal implants for surgical decision making. The individual surgeon instrumentation costs varied 10-fold based on the fusion construct used.<sup>29</sup> However, previous literature reported that PEEK cages were much more costly than structural allograft.<sup>29</sup>

PEEK spacers cost \$4930–\$5246, whereas structural allograft spacers are estimated to cost \$1220–\$3640.<sup>29</sup> Further studies are needed to determine the surgical effectiveness and cost savings related to the use of PEEK cages versus structural allograft in patients undergoing spinal fusion surgery.

Our study has several limitations. 1) No randomized controlled trials were included. 2) Only retrospective studies were included, which could be a source of selection bias. 3) The studies did not provide sufficient data regarding the different surgical approaches adopted between the 2 cohorts. 4) The indications for surgery and underlying clinical conditions were not always clear in the studies. 5) There was heterogeneity of PEEK cage assessment in one of the studies owing to inclusion of a national database.<sup>13</sup> 6) There were differences in the fusion assessment among the studies. 6) High-quality evidence for comparative analysis to form robust conclusions was lacking. Further prospective studies comparing structural allograft and PEEK implants following spinal fusion surgery with regard to subsidence rate, fusion assessment, and patient-reported outcome at long-term follow-up are required to better assess the effectiveness of each interbody spacer.

## CONCLUSIONS

At a mean follow-up of 12.9 months, structural body allograft provides better bony fusion compared with PEEK implants following spinal fusion surgery. However, further prospective studies are needed to compare the effectiveness of the 2 interbody spacers in patients undergoing single-level and multilevel spinal fusion procedures.

## REFERENCES

- Patel DV, Yoo JS, Karmarkar SS, Lamoutte EHSK. Interbody options in lumbar fusion. *J Spine Surg.* 2019;5(Suppl 1):S19-S24.
- Carter N, Gianulis EC, Moore MA. Allograft structural interbody spacers compared to PEEK cages in cervical fusion: benchtop and clinical evidence [online first]. *IntechOpen.* <https://doi.org/10.5772/intechopen.88091>. Available at: <https://www.intechopen.com/online-first/allograft-structural-interbody-spacers-compared-to-peek-cages-in-cervical-fusion-benchtop-and-clinic>. Accessed September 3, 2019.
- Miller LE, Block JE. Safety and effectiveness of bone allografts in anterior cervical discectomy and fusion surgery. *Spine (Phila Pa 1976).* 2011;36:2045-2050.
- Phan K, Hogan JA, Assem Y, Mobbs RJ. PEEK-Halo effect in interbody fusion. *J Clin Neurosci.* 2016;24:138-140.
- Samsell B, Softic D, Qin X, et al. Preservation of allograft bone using a glycerol solution: a compilation of original preclinical research. *Biomater Res.* 2019;23:5.
- Chong E, Pelletier MH, Mobbs RJ, Walsh WR. The design evolution of interbody cages in anterior cervical discectomy and fusion: a systematic review orthopedics and biomechanics. *BMC Musculoskelet Disord.* 2015;16:99.
- Brantigan JW, Steffee AD. A carbon fiber implant to aid interbody lumbar fusion: two-year clinical results in the first 26 patients. *Spine (Phila Pa 1976).* 1993;18:2106-2107.
- Cutler AR, Siddiqui S, Mohan AL, Hillard VH, Cerabona F, Das K. Comparison of polyetheretherketone cages with femoral cortical bone allograft as a single-piece interbody spacer in transforaminal lumbar interbody fusion. *J Neurosurg Spine.* 2006;5:534-539.
- Moher D, Liberati A, Tetzlaff J, Altman DG. Preferred reporting items for systematic reviews and meta-analyses: the PRISMA statement. *J Clin Epidemiol.* 2009;62:1006-1012.
- Ansari MT, Tsertsvadze A, Moher D. Grading quality of evidence and strength of recommendations. *PLoS One.* 2009;6:e1000151.
- Wan Z, Dai M, Miao J, Li G, Wood KB. Radiographic analysis of PEEK cage and FRA in adult spinal deformity fused to sacrum. *J Spinal Disord Tech.* 2014;27:327-335.
- Yoon SC, Sembrano JN, Santos ERG. Comparison of allograft and polyetheretherketone (PEEK) cage subsidence rates in anterior cervical discectomy and fusion (ACDF). *J Clin Neurosci.* 2017;38:118-121.
- Pirkle S, Kaskovich S, Cook DJ, Ho A, Shi LL, Lee MJ. Cages in ACDF are associated with a higher nonunion rate than allograft. *Spine (Phila Pa 1976).* 2019;44:384-388.
- Teton Z, Cheaney B II, Raslan A, Than K. Use of polyetheretherketone interbody devices for multi-level anterior cervical discectomy and fusion results in a three-fold higher rate of pseudarthrosis compared to structural allograft. Paper presented at: American Association of Neurological Surgery Annual Scientific Meeting. April 13-17, 2019. San Diego, CA.
- Hill CP, Strenge KB. Early clinical outcomes comparing porous PEEK, smooth PEEK, and structural allograft interbody devices for anterior cervical discectomy and fusion. *J Spine Neurosurg.* 2019;8:1.
- Krause KL, Obayashi JT, Bridges KJ, Raslan AM, Than KD. Fivefold higher rate of pseudarthrosis with polyetheretherketone interbody device than with structural allograft used for 1-level anterior cervical discectomy and fusion. *J Neurosurg Spine.* 2018;30:46-51.



17. Whitecloud TS. Modern alternatives and techniques for one-level discectomy and fusion. *Clin Orthop Relat Res.* 1999;359:67-76.
18. Almasi D, Iqbal N, Sadeghi M, Sudin I, Abdul Kadir MR, Kamarul T. Preparation methods for improving PEEK's bioactivity for orthopedic and dental application: a review. *Int J Biomater.* 2016; 2016:8202653.
19. Ma R, Tang T. Current strategies to improve the bioactivity of PEEK. *Int J Mol Sci.* 2014;15: 5426-5445.
20. Makino T, Tsukazaki H, Ukon Y, Tateiwa D, Yoshikawa H, Kaito T. The biological enhancement of spinal fusion for spinal degenerative disease. *Int J Mol Sci.* 2018;19:2430.
21. Selby MD, Clark SR, Hall DJ, Freeman BJC. Radiologic assessment of spinal fusion. *J Am Acad Orthop Surg.* 2012;20:694-703.
22. Brodsky AE, Kovalsky ES, Khalil MA. Correlation of radiologic assessment of lumbar spine fusions with surgical exploration. *Spine (Phila Pa 1976).* 1991;16(6 Suppl):S261-S265.
23. Buchowski JM, Liu G, Bunmaprasert T, Rose PS, Riew KD. Anterior cervical fusion assessment: surgical exploration versus radiographic evaluation. *Spine (Phila Pa 1976).* 2008;33:1185-1191.
24. Ploumis A, Mehbod A, Garvey T, Gilbert T, Transfeldt E, Wood K. Prospective assessment of cervical fusion status: plain radiographs versus CT-scan. *Acta Orthop Belg.* 2006;72:342-346.
25. Ghiselli G, Wharton N, Hipp JA, Wong DA, Jatana S. Prospective analysis of imaging prediction of pseudarthrosis after anterior cervical discectomy and fusion: computed tomography versus flexion-extension motion analysis with intra-operative correlation. *Spine (Phila Pa 1976).* 2011;36: 463-468.
26. McAfee PC, DeVine JG, Chaput CD, et al. The indications for interbody fusion cages in the treatment of spondylolisthesis: analysis of 120 cases. *Spine (Phila Pa 1976).* 2005;30(6 Suppl): S60-S65.
27. Nayak NR, Coats JM, Abdullah KG, Stein SC, Malhotra NR. Tracking patient-reported outcomes in spinal disorders. *Surg Neurol Int.* 2015;6(Suppl 19):S490-S499.
28. Karikari IO, Jain D, Owens TR, et al. Impact of subsidence on clinical outcomes and radiographic fusion rates in anterior cervical discectomy and fusion: a systematic review. *J Spinal Disord Tech.* 2014;27:1-10.
29. Epstein N. Iliac crest autograft versus alternative constructs for anterior cervical spine surgery: pros, cons, and costs. *Surg Neurol Int.* 2012;3(Suppl 3):S143-S156.

*Conflict of interest statement: The authors declare that the article content was composed in the absence of any commercial or financial relationships that could be construed as a potential conflict of interest.*

*Received 26 November 2019; accepted 2 January 2020*

*Citation: World Neurosurg. (2020) 136:101-109.*

*<https://doi.org/10.1016/j.wneu.2020.01.006>*

*Journal homepage: [www.journals.elsevier.com/world-neurosurgery](http://www.journals.elsevier.com/world-neurosurgery)*

*Available online: [www.sciencedirect.com](http://www.sciencedirect.com)*

*1878-8750/\$ - see front matter © 2020 Elsevier Inc. All rights reserved.*



## Fivefold higher rate of pseudarthrosis with polyetheretherketone interbody device than with structural allograft used for 1-level anterior cervical discectomy and fusion

Presented at the 2018 AANS/CNS Joint Section on Disorders of the Spine and Peripheral Nerves

Katie L. Krause, MD, PhD, James T. Obayashi, BS, Kelly J. Bridges, MD, Ahmed M. Raslan, MD, and Khoi D. Than, MD

Department of Neurological Surgery, Oregon Health & Science University, Portland, Oregon

**OBJECTIVE** Common interbody graft options for anterior cervical discectomy and fusion (ACDF) include structural allograft and polyetheretherketone (PEEK). PEEK has gained popularity due to its radiolucency and its elastic modulus, which is similar to that of bone. The authors sought to compare the rates of pseudarthrosis, a lack of solid bone growth across the disc space, and the need for revision surgery with the use of grafts made of allogenic bone versus PEEK.

**METHODS** The authors retrospectively reviewed 127 cases in which patients had undergone a 1-level ACDF followed by at least 1 year of radiographic follow-up. Data on age, sex, body mass index, tobacco use, pseudarthrosis, and the reoperation rate for pseudarthrosis were collected. These data were analyzed by performing a Pearson's chi-square test.

**RESULTS** Of 127 patients, 56 had received PEEK implants and 71 had received allografts. Forty-six of the PEEK implants (82%) were stand-alone devices. There were no significant differences between the 2 treatment groups with respect to patient age, sex, or body mass index. Twenty-nine (52%) of 56 patients with PEEK implants demonstrated radiographic evidence of pseudarthrosis, compared to 7 (10%) of 71 patients with structural allografts ( $p < 0.001$ , OR 9.82; 95% CI 3.836–25.139). Seven patients with PEEK implants required reoperation for pseudarthrosis, compared to 1 patient with an allograft ( $p = 0.01$ , OR 10.00; 95% CI 1.192–83.884). There was no significant difference in tobacco use between the PEEK and allograft groups ( $p = 0.586$ ).

**CONCLUSIONS** The results of this study demonstrate that the use of PEEK devices in 1-level ACDF is associated with a significantly higher rate of radiographically demonstrated pseudarthrosis and need for revision surgery compared with the use of allografts. Surgeons should be aware of this when deciding on interbody graft options, and reimbursement policies should reflect these discrepancies.

<https://thejns.org/doi/abs/10.3171/2018.7.SPINE18531>

**KEYWORDS** ACDF; anterior cervical discectomy and fusion; pseudarthrosis; PEEK; allograft

ANTERIOR cervical discectomy and fusion (ACDF) is one of the most common neurosurgical procedures performed for the treatment of cervical myelopathy and radiculopathy.<sup>1</sup> Although immediate symptomatic relief is generally due to decompression of the affected neural structures, long-term success is dependent on the placement of an appropriate interbody graft within the

disc space to maintain disc and foraminal height, restore cervical lordosis, and promote bone fusion.<sup>11,13</sup>

As surgeons continue to refine this common procedure, options for graft material have increasingly multiplied. An autograft, often obtained from the patient's anterior iliac crest, is considered to be the gold standard due to its lack of histocompatibility difference from the removed disc,

**ABBREVIATIONS** ACDF = anterior cervical discectomy and fusion; DBM = demineralized bone matrix; PEEK = polyetheretherketone; QALY = quality-adjusted life-year; rhBMP-2 = recombinant human bone morphogenetic protein-2.

**SUBMITTED** April 27, 2018. **ACCEPTED** July 19, 2018.

**INCLUDE WHEN CITING** Published online October 30, 2018; DOI: 10.3171/2018.7.SPINE18531.

which could lead to graft rejection, and its ability to form a solid fusion construct.<sup>17,22</sup> Harvesting bone for an autograft, however, comes with added morbidity, including donor site pain, stress fractures, and injury to the lateral femoral cutaneous nerve, as well as increased operative time, blood loss, and rate of surgical infection.<sup>13,19,22</sup> Allograft substitutes, including cortical, cancellous, and composite cadaver bone, have been employed to circumvent these complications, but they come with the theoretical risk of increased disease transmission, such as hepatitis and HIV, for which the estimated risks of disease spread are reported to be 0.01% and 0.03%, respectively.<sup>6,14</sup>

More recently, synthetic interbody fusion devices have been developed, which are primarily made from carbon fiber, titanium, or polyetheretherketone (PEEK).<sup>28</sup> The PEEK cage, in particular, has gained significant popularity due to its radiolucent properties and its elastic modulus, which is similar to that of bone.<sup>4,8,12</sup> Furthermore, the use of PEEK cages results in increased billing per surgical level compared to allograft,<sup>23</sup> which may further drive graft selection. Of note, for single-level cases, if a PEEK cage is used without a plate, the number of work relative value units is fewer than if a structural allograft is used with a plate (approximately 36 vs 49, depending on the payor). It seems conceivable that PEEK, a plastic material, would promote less bone fusion than a structural cadaveric bone allograft, even if the PEEK cage were packed with bone. Thus, we performed the largest retrospective cohort study to date to examine the incidence of radiographically demonstrated pseudarthrosis and subsequent reoperations in patients who underwent a 1-level ACDF with either a PEEK or structural allograft implant.

## Methods

In this retrospective, single-center study, all consecutive 1-level ACDF procedures performed at the Oregon Health & Science University between July 2011 and July 2016 were reviewed. Thirteen different attending surgeons (9 neurological surgeons and 4 orthopedic surgeons) performed the operative procedures. Any adult patient undergoing a 1-level ACDF for degenerative disease or trauma was included. Patients who did not have at least 1 year of follow-up with either a cervical x-ray study or CT scan were excluded. Implant selection, duration of follow-up, and the acquisition of follow-up imaging were dependent on the practice pattern of the individual surgeon. The study was approved by the local institutional review board, with a waiver of consent.

Electronic medical records were reviewed for demographic data, patient smoking status, type of graft material used, and evidence of pseudarthrosis. The presence of pseudarthrosis was defined as the lack of solid bone growth across the disc space at 1 or more years of radiographic follow-up. The primary investigators and an attending neuroradiologist independently reviewed all postoperative imaging studies. Records were further reviewed for any additional surgical intervention that was warranted beyond the index surgery. All records were also reviewed for the occurrence of postoperative infection.

Statistical analysis was undertaken using SPSS Statis-

tics version 24 (IBM Corp.), and p values were considered significant at  $< 0.05$ . Pearson correlation tests were used to determine whether there were statistically significant correlations between the rates of pseudarthrosis and of reoperations, and the graft materials (PEEK vs allograft materials). A Pearson correlation test was also used to determine if there was a statistically significant level of correlation between smoking history and graft material in patients in whom pseudarthrosis was confirmed. A Fisher exact test was used to determine the correlation between pseudarthrosis and the reoperation rate for PEEK grafts associated with a plate. A Student t-test was used to determine differences between the times of radiographic follow-up.

Mean results for the treatment groups are expressed as means  $\pm$  standard deviations.

## Results

Four hundred eight patients underwent 1-level ACDF during the collection period; of these, 211 (51.7%) received PEEK implants, 185 (45.3%) received structural allograft implants, and 12 (2.9%) received iliac crest autografts. Of the 408 patients, 127 (31%) met the study's inclusion criteria: 56 (44%) with PEEK implants and 71 (56%) with structural allograft implants. The allograft implants included composite (61/71), cortical (8/71), or cancellous (2/71) materials. All PEEK cages were filled with nonstructural allograft in the form of demineralized bone matrix (DBM; 47/56) or a local autograft (9/56). The mean age of patients was  $51 \pm 14.9$  years in the PEEK group and  $53 \pm 13.0$  years in the allograft group. There was no significant difference in body mass index or smoking status between patients in the PEEK and allograft groups (Table 1). The overall 25% rate of smokers was slightly higher than the 17% rate in the overall US population.<sup>9</sup> In both groups, the majority of procedures were performed for degenerative changes: 1 procedure was performed for trauma in the PEEK group (2%) and 11 procedures were performed for trauma in the allograft group (15.5%) ( $p = 0.009$ ). Excluding patients who underwent ACDF for trauma yielded similar pseudarthrosis rates: 27 (48.2%) of 56 patients in the PEEK group and 5 (8%) of 62 patients in the structural allograft group.

Patient imaging at the 1-year follow-up included x-ray studies in 110 patients (86.6%) and CT scanning in 17 patients (13.4%). In the PEEK group, 45 (80.4%) of 56 pa-

TABLE 1. Patient demographics

Factor	Structural Allograft Group	PEEK Group	Total
Patients	71	56	127
Age in yrs (mean $\pm$ SD)	$51 \pm 14.9$	$53 \pm 13.0$	$51.7 \pm 14.2$
Males	34	21	55
Females	37	35	72
Smokers	17 (24)	15 (27)	32 (25)
BMI (mean $\pm$ SD)	$28.4 \pm 0.6$	$29.1 \pm 0.7$	$28.7 \pm 0.6$

Unless otherwise specified, values represent numbers of patients (%), if given). There was no statistically significant difference between groups in any category.

tients underwent x-ray studies compared to 65 (91.5%) of 71 patients in the structural allograft group; the difference in these values was not statistically significant ( $p = 0.115$ ). Average radiographic follow-up was longer in the PEEK group than in the structural allograft group: 21 versus 16 months, respectively ( $p = 0.02$ ). Of the 56 patients who received PEEK implants, 29 (51.8%) had demonstrated radiographic evidence of pseudarthrosis at 1 or more years after follow-up, as seen on a cervical x-ray film or CT scan (Fig. 1). In contrast, only 7 (10%) of the 71 patients with structural allograft implants had radiographic evidence of pseudarthrosis ( $p < 0.001$ , OR 9.82; 95% CI 3.8–25.1). Of patients with pseudarthrosis, 7 patients with PEEK implants (24.1%) required a revision operation for pseudarthrosis, compared to only 1 patient with a structural allograft (14.3%) ( $p = 0.01$ , OR 10.00; 95% CI 1.192–83.884) (Table 2). Clinical indications for revision surgery for the 7 patients with PEEK implants included persistent radiculopathy (6/7), myelopathy (2/7), or chronic, debilitating neck pain (1/7). One of the 7 patients required revision surgery to correct completely fractured hardware with radiculopathy. The types of revision surgery included a redo ACDF, a posterior instrumented fusion, and a combination of redo anterior fusion combined with posterior fusion.

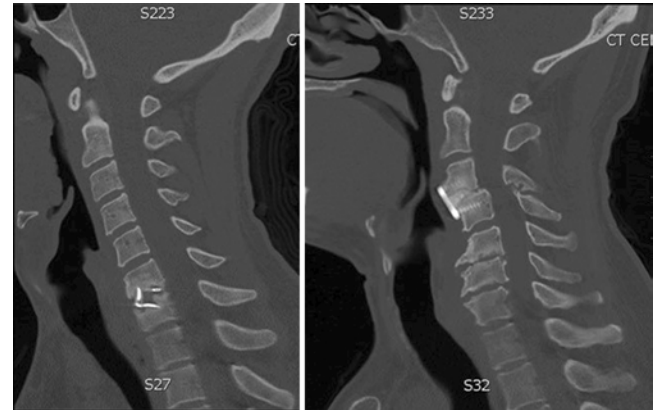
The 1 patient who underwent revision ACDF surgery in the allograft group initially received a composite bone graft and displayed clinical indications of persistent radiculopathy. Interestingly, the graft for this patient was changed to a PEEK implant upon revision surgery. This was also the only patient in whom a postoperative wound infection developed after revision surgery; the infection was treated with operative washout and a course of antibiotics. There were no reports of postoperative transmission of hepatitis or HIV in either group.

The incidence of pseudarthrosis in patients who had received PEEK implants requiring plate and screw fixation was also examined. The majority of PEEK implants were stand-alone devices with no associated plate devices (46/56 implants, 82.1%). Of the 10 patients who received PEEK implants with an associated plate, there was radiographic evidence of pseudarthrosis in 3 patients, 2 of whom required revision surgery. Compared to stand-alone PEEK implants, there was no significant correlation between a PEEK implant associated with a plate and the incidence of pseudarthrosis ( $p = 0.171$ ) or revision surgery ( $p = 0.596$ ). In other words, PEEK implants led to higher pseudarthrosis rates than structural allografts regardless of whether the PEEK implants were stand-alone or supplemented with a plate and screws. However, the number of patients with a plated PEEK implant was very small ( $n = 10$ ) and insufficient to draw strong conclusions.

Smoking status was further examined in patients with radiographic pseudarthrosis: 11 (37.9%) of 29 patients with pseudarthrosis in the PEEK group smoked tobacco, whereas 4 (57.1%) of 7 patients with pseudarthrosis in the allograft group smoked ( $p = 0.586$ ) (Table 2). Of all patients with pseudarthrosis, only 1 patient in the PEEK group was on a long-term regimen of steroids for lupus.

## Discussion

This retrospective study—the largest ever in which



**FIG. 1.** Sagittal x-ray films obtained in a patient with a PEEK interbody graft and pseudarthrosis (**left**) and a patient with a structural allograft implant (**right**) healed 1 year after surgery.

PEEK implants have been compared with structural allografts for ACDF—demonstrates an alarmingly high rate of radiographic evidence of pseudarthrosis in patients who received PEEK grafts while undergoing a 1-level ACDF compared to those who received structural allografts. After at least 1 year of radiographic follow-up, there was a fivefold higher incidence of pseudarthrosis in patients with PEEK cages and almost a doubled rate of subsequent revision surgery.

Since their approval by the US Food and Drug Administration in 1998,<sup>12,21</sup> PEEK implants have been a widely accepted choice as an interbody spacer. A recent study surveying 5334 surgeons from the Global AO Spine database found that PEEK cages make up 84% of cages selected for the graft component of an ACDF.<sup>28</sup> PEEK implants have gained popularity because their elastic modulus is close to that of human bone, and in contrast to metallic cages, PEEK cages are composed of radiolucent material and produce less artifact on postoperative imaging.<sup>5</sup> Furthermore, PEEK does not come with the risk of disease transmission that allograft spacers theoretically carry. However, the inherent bio-inertness of PEEK comes with the significant disadvantage of its being less likely to integrate with organic bone tissue.<sup>21</sup> In vitro studies have demonstrated that when mesenchymal cells are cultured on PEEK material, they do not express known markers of bone formation, including alkaline phosphatase or osteocalcin.<sup>15</sup> Furthermore, mesenchymal cultures grown on PEEK have significantly higher levels of interleukin-1 $\beta$ , which is associated

**TABLE 2.** Comparison of pseudarthrosis, need for revision surgery, and smoking status between the structural allograft and PEEK implant groups

Factor	Structural Allograft Group	PEEK Group	p Value
Pseudarthrosis on imaging studies	7 (10)	29 (52)	$\leq 0.001$
Revision surgery	1 (14)	7 (24)	0.01
Smokers w/ pseudarthrosis	4 (57)	11 (38)	0.59

Unless otherwise specified, values represent numbers of patients (%).



with the formation of fibrous tissue rather than bone tissue. Cells cultured on PEEK have also been demonstrated to have significantly higher levels of necrosis, DNA damage, and apoptosis.<sup>16</sup> These *in vitro* studies are supported in an *in vivo* sheep model, which also demonstrated PEEK cages surrounded by fibrous connective tissue, preventing bone integration and potentially resulting in nonunion.<sup>24</sup>

In the clinical setting, there is little evidence for the superiority of PEEK over allograft, although studies describing well-controlled, direct comparisons between PEEK and allograft are limited. A recent meta-analysis found only 10 studies that directly compared PEEK to autograft, allograft, or other synthetic cages (titanium and carbon fiber). However, within those 10 studies there were no significant differences in fusion rates or clinical outcomes between PEEK and other graft materials.<sup>10</sup> In only 2 of those 10 studies did researchers directly compare PEEK to allograft. Vaidya et al.<sup>25</sup> performed a retrospective chart review of 46 consecutive cases of ACDF in which they compared patients treated with PEEK cages filled with recombinant human bone morphogenetic protein-2 (rhBMP-2) with patients treated with allograft interbody spacers and DBM at a single institution. Follow-up x-ray studies at 1.5–6 months postoperatively demonstrated that the PEEK cages filled with rhBMP-2 consistently exhibited 100% endplate resorption, which was said to have often been mistaken as infection by radiologists' interpretations. In contrast, there was no endplate resorption in any of the patients treated with allograft and DBM, with only "simple and progressive blurring" of the endplate junction, indicating ongoing fusion. However, at the 2-year follow-up, there was no significant difference in radiographic or clinical outcomes between the two groups, as measured by Cervical Oswestry Scale scores or visual analog scale scores. Subsequent cost analysis demonstrated that the cost of implants treated with PEEK and rhBMP-2 was more than 3 times the cost of those treated with allografts and DBM, which led the authors to ultimately abandon the use of PEEK and rhBMP-2 in lieu of the less expensive and equally effective allograft spacer. Another retrospective review<sup>20</sup> compared PEEK and rhBMP-2 with allograft and rhBMP-2 for both ACDF and lumbar interbody fusion. In those patients who underwent an ACDF ( $n = 34$ ), the PEEK and rhBMP-2 groups had slightly higher fusion rates than the allograft group (91% vs 81%, respectively), with 1 PEEK cage displaying cage migration. Similar to the findings of Vaidya et al.,<sup>25</sup> there was 100% endplate resorption with the use of rhBMP-2. There was a 50% subsidence rate in all patients.<sup>20</sup>

This potential for subsidence is one main concern cited in the literature as a disadvantage of allografts, which can lead to loss of disc and foraminal height, increased angulation, and nonunion.<sup>2,3,18</sup> However, in a recent retrospective study, researchers compared subsidence rates between PEEK and allograft cages and found that there was no significant difference between the PEEK (29%) and allograft (28%) groups. Furthermore, this study by Yson et al. demonstrated that even those patients who did have subsidence did not display any clinical difference from those who did not, as measured by the Neck Disability Index and the visual analog scale.<sup>29</sup>

Our findings have a wider implication on a systems level, as the number of ACDF procedures performed continues to increase, and reimbursement policies continue to evolve. Between 1992 and 2005, the rate of ACDFs grew by 206% in patients older than 65 years,<sup>27</sup> which is in line with the significant increase in general American healthcare spending, which rose to \$2.6 trillion in 2010. As such, there has been increased scrutiny regarding the cost-effectiveness of all spinal procedures.<sup>26</sup> In 1 study, a Markov decision model was used to determine the most effective graft (PEEK, allograft, or autograft) for a 1-level ACDF in terms of cost and quality of life. Cost was defined as the total sum of hospital, physician, and graft fees based on Current Procedural Terminology codes. The code designated for a PEEK interbody cage (22851) has a significantly higher reimbursement rate than that for a structural allograft (20931),<sup>23</sup> with a work relative value unit of 6.7 versus 1.8, respectively. As such, there was a significantly higher total cost for an ACDF with a PEEK cage (estimated total cost of \$18,314) than for the same procedure in which an allograft cage was used (estimated total cost of \$12,539). Virk et al. further examined the cost of quality-adjusted life-years (QALYs) gained by each graft type. PEEK was reported to be the most expensive, costing \$3220/QALY, compared to allograft at \$2358/QALY and autograft at \$2413/QALY.<sup>26</sup> This economic discrepancy is further widened by synthetic cage billing per level of placement, while allograft billing is once per surgery, regardless of the number of levels instrumented.

As Kersten et al. described in the review accompanying their meta-analysis, data regarding clinical outcomes of PEEK cages come mostly from noncomparative cohort studies and a few randomized control trials.<sup>10</sup> Compared with data from previous studies, the advantage of the data we present here is that it offers a direct comparison of the incidence of radiographic pseudarthrosis between patients who received a PEEK cage and those who received a structural allograft in a 1-level ACDF. Furthermore, according to our review of previous studies, our study has the largest cohort of patients. However, our study does have limitations, which are inherent to its retrospective nature. A total of 13 different surgeons performed these procedures, making standardization of graft selection and the operative procedure difficult, although the similarity of the results across multiple surgeons does suggest generalizability of our findings. Differences between surgeons and changes in practice patterns were not evaluated. Confounders may stem from the lack of uniformity of physical graft placement, the type of structural allograft used (although the vast majority were composite), and the materials used to pack the PEEK cages (although the vast majority were packed with allograft and DBM). Many patients did not have 1 year of follow-up and thus were not included in the final analysis.

Another limitation of this study is that 2 different imaging modalities (x-ray and CT) were used to evaluate fusion. Ideally, all patients would have received gold-standard CT scanning, although the use of CT leads to increased costs as well as greater radiation exposure. One might even argue that complete bone bridging from endplate to endplate is not essential. As is the case with de-

vices covered by plasma spray or sintered beads, PEEK does not undergo creeping bone substitution, as it just needs to be anchored at the ends to bone and will continue its load-bearing support irrespective of bone growth through the cage itself. As such, another imaging modality that could have been useful for assessing pseudarthrosis in this study, and which may be considered in future studies, is the flexion-extension x-ray study, which has been shown to provide a higher level of evidence for fusion.<sup>7</sup>

Also, as mentioned, the rate of cigarette smoking in the patient population of this study is slightly higher than the percentage of smokers in the overall US population, which may affect the generalizability of the results. In addition, the PEEK group in the present study also had a higher percentage of cigarette smokers than the structural allograft group. Although this finding was not statistically significant, it suggests that the two groups were not ideally matched. One should note, however, that the prevalence of smoking in patients with pseudarthrosis was higher in patients with structural allografts than in those with PEEK devices. This study is also lacking objective clinical data with validated outcome surveys, which will be a focus of future prospective studies. The ideal future study would be a multicenter study with a minimum of 2 years of follow-up and a better definition of the goal of the implants.

## Conclusions

The results of this study suggest that the use of PEEK cages is associated with a significantly increased risk for bone nonunion and revision surgery compared to the use of structural allograft implants, at least at our institution. Thus, surgeons should consider these risks when deciding among the many graft choices available for an ACDF. Furthermore, reimbursement policies to reduce the cost discrepancy between PEEK and allograft should be advocated.

## Acknowledgments

The authors thank Shirley McCartney, PhD, and Sharon Kinser for editorial assistance.

## References

1. Bible JE, Kang JD: Anterior cervical discectomy and fusion: surgical indications and outcomes. **Semin Spine Surg** 28:80–83, 2016
2. Bishop RC, Moore KA, Hadley MN: Anterior cervical interbody fusion using autogeneic and allogeneic bone graft substrate: a prospective comparative analysis. **J Neurosurg** 85:206–210, 1996
3. Chau AMT, Mobbs RJ: Bone graft substitutes in anterior cervical discectomy and fusion. **Eur Spine J** 18:449–464, 2009
4. Chen F, He W, Mahaney K, Noeller J, Mhanna N, Viljoen S, et al: Alternative grafts in anterior cervical fusion. **Clin Neurol Neurosurg** 115:2049–2055, 2013
5. Cizek GR, Boyd LM: Imaging pitfalls of interbody spinal implants. **Spine (Phila Pa 1976)** 25:2633–2636, 2000
6. Delloye C, Cornu O, Druze V, Barbier O: Bone allografts: what they can offer and what they cannot. **J Bone Joint Surg Br** 89:574–579, 2007
7. Ghiselli G, Wharton N, Hipp JA, Wong DA, Jatana S: Prospective analysis of imaging prediction of pseudarthrosis after anterior cervical discectomy and fusion: computed tomography versus flexion-extension motion analysis with intraoperative correlation. **Spine (Phila Pa 1976)** 36:463–468, 2011
8. Hee HT, Kundnani V: Rationale for use of polyetheretherketone polymer interbody cage device in cervical spine surgery. **Spine J** 10:66–69, 2010
9. Jamal A, Phillips E, Gentzke AS, Homa DM, Babb SD, King BA, et al: Current cigarette smoking among adults—United States, 2016. **MMWR Morb Mortal Wkly Rep** 67:53–59, 2018
10. Kersten RFMR, van Gaalen SM, de Gast A, Öner FC: Polyetheretherketone (PEEK) cages in cervical applications: a systematic review. **Spine J** 15:1446–1460, 2015
11. Kolstad F, Nygaard ØP, Andresen H, Leivseth G: Anterior cervical arthrodesis using a “stand alone” cylindrical titanium cage: prospective analysis of radiographic parameters. **Spine (Phila Pa 1976)** 35:1545–1550, 2010
12. Kurtz SM, Devine JN: PEEK biomaterials in trauma, orthopedic, and spinal implants. **Biomaterials** 28:4845–4869, 2007
13. Maharaj MM, Phan K, Mobbs RJ: Anterior cervical discectomy and fusion (ACDF) autograft versus graft substitutes: what do patients prefer?—A clinical study. **J Spine Surg** 2:105–110, 2016
14. Ng VY: Risk of disease transmission with bone allograft. **Orthopedics** 35:679–681, 2012
15. Olivares-Navarrete R, Gittens RA, Schneider JM, Hyzy SL, Haithcock DA, Ullrich PF, et al: Osteoblasts exhibit a more differentiated phenotype and increased bone morphogenetic protein production on titanium alloy substrates than on polyether-ether-ketone. **Spine J** 12:265–272, 2012
16. Olivares-Navarrete R, Hyzy SL, Slosar PJ, Schneider JM, Schwartz Z, Boyan BD: Implant materials generate different peri-implant inflammatory factors: poly-ether-ether-ketone promotes fibrosis and microtextured titanium promotes osteogenic factors. **Spine (Phila Pa 1976)** 40:399–404, 2015
17. Pollock R, Alcelik I, Bhatia C, Chuter G, Lingutla K, Budithi C, et al: Donor site morbidity following iliac crest bone harvesting for cervical fusion: a comparison between minimally invasive and open techniques. **Eur Spine J** 17:845–852, 2008
18. Rhee JM, Patel N, Yoon ST, Franklin B: High graft resorption rates with dense cancellous allograft in anterior cervical discectomy and fusion. **Spine (Phila Pa 1976)** 32:2980–2984, 2007
19. Schnee CL, Freese A, Weil RJ, Marcotte PJ: Analysis of harvest morbidity and radiographic outcome using autograft for anterior cervical fusion. **Spine (Phila Pa 1976)** 22:2222–2227, 1997
20. Sethi A, Craig J, Bartol S, Chen W, Jacobson M, Coe C, et al: Radiographic and CT evaluation of recombinant human bone morphogenetic protein-2-assisted spinal interbody fusion. **AJR Am J Roentgenol** 197:W128–W133, 2011
21. Shimizu T, Fujibayashi S, Yamaguchi S, Otsuki B, Okuzu Y, Matsushita T, et al: In vivo experimental study of anterior cervical fusion using bioactive polyetheretherketone in a canine model. **PLoS One** 12:e0184495, 2017
22. Silber JS, Anderson DG, Daffner SD, Brislin BT, Leland JM, Hilibrand AS, et al: Donor site morbidity after anterior iliac crest bone harvest for single-level anterior cervical discectomy and fusion. **Spine (Phila Pa 1976)** 28:134–139, 2003
23. Singh K, Qureshi S: ISASS Policy Statement—cervical interbody. **Int J Spine Surg** 8:13, 2014
24. Toth JM, Wang M, Estes BT, Scifert JL, Seim HB III, Turner AS: Polyetheretherketone as a biomaterial for spinal applications. **Biomaterials** 27:324–334, 2006
25. Vaidya R, Carp J, Sethi A, Bartol S, Craig J, Les CM: Complications of anterior cervical discectomy and fusion using



- recombinant human bone morphogenetic protein-2. **Eur Spine J** 16:1257–1265, 2007
26. Virk SS, Elder JB, Sandhu HS, Khan SN: The cost effectiveness of polyetheretherketone (PEEK) cages for anterior cervical discectomy and fusion. **J Spinal Disord Tech** 28:E482–E492, 2015
  27. Wang MC, Kreuter W, Wolfla CE, Maiman DJ, Deyo RA: Trends and variations in cervical spine surgery in the United States: Medicare beneficiaries, 1992 to 2005. **Spine (Phila Pa 1976)** 34:955–963, 2009
  28. Yoon ST, Konopka JA, Wang JC, Youssef JA, Meisel HJ, Brodke DS, et al: ACDF graft selection by surgeons: survey of AOSpine members. **Global Spine J** 7:410–416, 2017
  29. Yson SC, Sembrano JN, Santos ERG: Comparison of allograft and polyetheretherketone (PEEK) cage subsidence rates in anterior cervical discectomy and fusion (ACDF). **J Clin Neurosci** 38:118–121, 2017

## Disclosures

The authors have no personal, financial, or institutional interest in any of the drugs, materials, or devices described in this article. Dr. Raslan reports being a consultant to Abbott, and Dr. Than reports being a consultant to Bioventus.

## Author Contributions

Conception and design: Than. Acquisition of data: Krause, Bridges. Analysis and interpretation of data: Than, Krause, Obayashi. Drafting the article: Than, Krause. Critically revising the article: Than, Krause, Bridges. Reviewed submitted version of manuscript: Than, Obayashi, Bridges, Raslan. Approved the final version of the manuscript on behalf of all authors: Than. Statistical analysis: Than, Krause, Obayashi, Raslan. Administrative/technical/material support: Than. Study supervision: Than.

## Supplemental Information

### Previous Presentations

Data shown in this report were presented by Dr. Krause at the Spine Summit 2018—34th Annual Meeting of the Section on Disorders of the Spine and Peripheral Nerves (Abstract no. 122, Top Abstracts Concurrent Session), March 14–17, 2018, Orlando, Florida; and in Abstracts of the 2018 AANS/CNS Joint Section on Disorders of the Spine and Peripheral Nerves Annual Meeting. *Neurosurg Focus* 44(3):A1–A109, 2018.

## Correspondence

Khoi D. Than: Oregon Health & Science University, Portland, OR. [thank@ohsu.edu](mailto:thank@ohsu.edu).

## CERVICAL SPINE

# Cages in ACDF are Associated With a Higher Nonunion Rate Than Allograft

## *A Stratified Comparative Analysis of 6130 Patients*

Sean Pirkle, BA, Samuel Kaskovich, BSA, David J. Cook, BA, BEng, Alisha Ho, BA,  
Lewis L. Shi, MD, and Michael J. Lee, MD

**Study Design.** A retrospective database review.

**Objective.** The purpose of this study was to analyze the rate of nonunion in patients treated with structural allograft and intervertebral cages in anterior cervical discectomy and fusion (ACDF).

**Summary of Background Data.** Existing literature consists primarily of single-center studies with inconsistent findings.

**Methods.** We performed a retrospective analysis of 6130 patients registered in the PearlDiver national database through Humana Insurance from 2007 to 2016. All ACDF patients with anterior plating who were active in the database for at least 1 year were included in the study. Patients with a fracture history within 1 year of intervention, past arthrodesis of hand, foot, or ankle, or a planned posterior approach were excluded from the study. Patients were stratified by number of levels treated, tobacco use, and diabetic condition. Nonunion rates of structural allograft and intervertebral cage groups after 1 year were compared using Chi-squared analyses.

**Results.** Four thousand sixty-three patients were included in the allograft group, while 2067 were included in the cage group. Overall nonunion rates were significantly higher in the cage group (5.32%) than in allograft group (1.97%) ( $P < 0.01$ ). When controlling for confounders, increased rates of nonunion were consistently observed in the cage group, achieving statistical significance in 25 of the 26 analyses.

**Conclusion.** The increased rate of nonunion associated with intervertebral cages may suggest the superiority of allograft over cages in ACDF.

**Key words:** ACDF, allograft, anterior cervical discectomy and fusion, cervical spine, fusion rate, intervertebral cage, nonunion, PEEK cage.

**Level of Evidence:** 3

**Spine 2019;44:384–388**

Anterior cervical discectomy and fusion (ACDF) is widely recognized as a highly successful surgical treatment of cervical radiculopathy and myelopathy.<sup>1,2</sup> Anterior decompression alone of the neural elements may result in spinal instability and pain, and thus, a concurrent arthrodesis is performed to achieve stability. The technique, initially performed with harvesting of autologous bone graft from the ilium, has since been modified by the utilization of allograft, and more recently, intervertebral cages with bone graft material. The importance of achieving fusion is generally agreed upon<sup>3</sup> in that the failure to achieve fusion is associated with a higher likelihood of symptoms and a higher likelihood for revision surgery.

Although allograft does not share the same osteoinductive and osteogenetic properties as autologous iliac crest bone graft, the distinct advantage of the use of allograft is the avoidance of the morbidity of iliac crest bone graft harvest. Allograft, despite its biological inferiority to autograft, does retain osteoconductivity and has been demonstrated in the literature to have high fusion rates.<sup>4</sup> Intervertebral cages in the cervical spine are designed to provide structural support between vertebral bodies and to allow bone fusion to occur within and around the cage. However, the cage itself carries no biological properties to promote fusion formation. Furthermore, the cage itself does occupy surface area and intervertebral volume for fusion mass to form that would otherwise have been occupied by a structural graft, auto or allo. This may decrease the likelihood of achieving solid arthrodesis as compared to structural bone graft. Despite these theoretical concerns, there has been a widespread enthusiasm for the use of intervertebral cages in anterior cervical discectomy and arthrodesis. Yoon *et al*,<sup>3</sup> in an international survey of spine surgeons, reported that the majority (64%) utilize cages as the

From the Department of Orthopaedic Surgery and Rehabilitation Medicine, University of Chicago Medical Center, Chicago, IL.

Acknowledgment date: May 30, 2018. First revision date: August 1, 2018. Acceptance date: August 9, 2018.

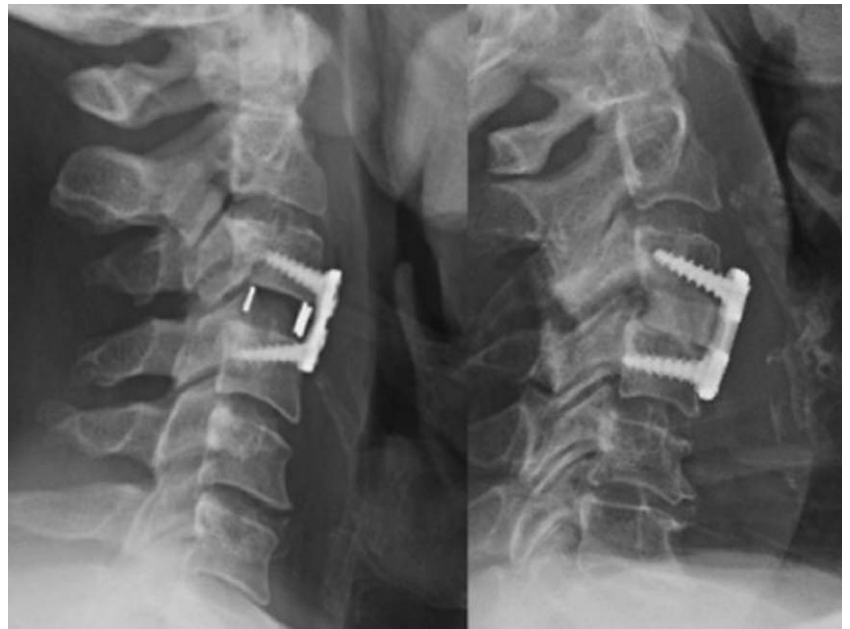
The device(s)/drug(s) is/are FDA-approved or approved by corresponding national agency for this indication.

No funds were received in support of this work.

Relevant financial activities outside the submitted work: grants.

Address correspondence and reprint requests to Sean Pirkle, BA, 5120 S Greenwood Ave, Apt #2, Chicago, IL 60615;  
E-mail: Sean.Pirkle@uchospitals.edu

DOI: 10.1097/BRS.0000000000002854



**Figure 1.** Single-level ACDF with cage and anterior instrumentation (left). Single-level ACDF with allograft and anterior instrumentation (right).

structural graft component. In North America, 36% of surgeons reported using cages in ACDF.<sup>3</sup>

Although there is extensive literature on fusion rates in ACDF, there are few studies comparing fusion rates in ACDF when using a cage *versus* a structural bone graft.<sup>5–9</sup> In addition, as fusion rates are fairly high for ACDF in general, small comparative studies are unlikely to have sufficient power to ascertain whether a difference in fusion rate exists or not. A higher sample size is needed to statistically demonstrate a significant difference or nondifference in fusion rates between the two techniques.

Using the PearlDiver database, we hypothesized that the use of an intervertebral cage in ACDF would be associated with a higher nonunion rate when compared with the fusion rates of ACDF using structural bone graft.

## MATERIALS AND METHODS

We performed a retrospective review of the Humana subset of the PearlDiver Patient Record Database. This is a commercially available dataset with millions of records from the nationwide Humana health insurance provider. In this dataset, queries can be conducted by Current Procedural Terminology (CPT) coding and International Classification of Diseases (ICD) 9th and 10th revision coding.

We utilized CPT 22551 and queried for patients who had undergone ACDF. Specifically, we selected for patients who had undergone (1) ACDF (22551), (2) structural allograft only (20931) or allograft with cage placement (22851), and (3) anterior instrumentation (22845, 22846) (Figure 1). In this population, we selected only patients who had at least 1-year follow-up after their index ACDF procedure. Any use of autologous iliac crest bone graft in ACDF was excluded from this study.

As our goal was to examine the effect of the intervertebral cage, we excluded patients who had a posterior arthrodesis

(22600) within 3 months of their ACDF, as this may have been a part of a planned staged procedure. We also excluded patients who may have had other concurrent orthopedic arthrodesis CPT codes in this perioperative period as well. In addition, we excluded patients with an ICD-9 or ICD-10 coding of fracture (Supplementary Table 1, <http://links.lww.com/BRS/B383>). The reason for these exclusions was to ensure that a “nonunion” code was in reference to the ACDF and not another source such as fracture healing or an alternate body site of fusion.

After our initial univariate analysis, we then performed a stratified analysis controlling for one significant variable (Table 1), then two (Table 2), and then three significant variables (Table 3). In order to determine differences in nonunion rates between the no cage and cage groups, we conducted Chi-squared tests of independence with an alpha level of 0.05 in all of our analyses.

## RESULTS

We identified 6130 patients who underwent ACDF with cage or allograft, anterior plating, and without concurrent or delayed posterior arthrodesis in the Humana subsection of the PearlDiver data registry. Of these, 66% (4063) were treated with allograft and 34% (2067) were treated with a cage device. The distribution of tobacco users, diabetics, and different levels of surgery were not observed to be statistically different between the cage group and allograft group ( $P > 0.05$ ).

In our univariate analysis of nonunion, we observed that patients with a cage experienced a rate of 5.32% and those with allograft 1.97% ( $P < 0.0001$ ). We also observed statistically increased rates of nonunion for diabetics, multiple levels, and tobacco use ( $P < 0.0001$ ). In all subanalyses controlling for confounding variables, we observed a higher rate of nonunion with the use of the cage as compared to the

**TABLE 1. Stratified Analysis; Nonunion Rates Between Allograft and Cage, After Controlling for Number of Levels Treated, Diabetes Status, and Tobacco Use**

	Allograft	Cage	P
One-level ACDF	1.9% (35/1835)	4.2% (35/843)	0.0007
Two-level ACDF	1.7% (28/1641)	6.1% (56/921)	<0.0001
3+ level ACDF	2.9% (17/587)	6.3% (19/303)	0.0155
Diabetes +	2.6% (44/1692)	8.3% (61/738)	<0.0001
Diabetes –	1.5% (36/2371)	3.7% (49/1329)	<0.0001
Tobacco +	2.7% (60/2195)	6.7% (69/1034)	<0.0001
Tobacco –	1.1% (20/1868)	4.0% (41/1033)	<0.0001

ACDF indicates anterior cervical discectomy and fusion.

allograft group. When controlling for one additional variable (Table 1), we observed that the use of the cage was significantly associated with a higher rate of nonunion in all subanalyses.

When controlling for two additional variables, we observed the use of the cage to be significantly associated with a higher rate of nonunion in 12 of the 13 possible subanalyses (Table 2). Three subanalyses were not possible (three-level ACDF/Tobacco –; three-level ACDF Diabetes –; Tobacco –/Diabetes –) group because the number of nonunions was less than 11. For patient privacy compliance in the PearlDiver data, when the sample size is less than 11, the true value is rendered as “–1.” In these cases, the number may be anywhere between 1 and 11 patients. In some cases, we were able to use the 11 values as a conservative estimate and still perform our analysis. For example, in the two-level ACDF/Tobacco – group, there were 11 or less patients with nonunion in the allograft group, whereas

there were 22 patients with nonunion in the cage group. In this case, we assigned the highest possible nonunion rate (11 patients) in the allograft group and still observed a statistically significant difference between the allograft and cage group.

When controlling for three additional variables (Table 3), we observed a statistically higher nonunion rate in the cage group in all subanalyses that were possible. Of the 12 possible permutations, only five subanalyses had sufficient data to allow for analysis. The remaining seven subanalyses had nonunion numbers of less than 11 in both groups. As the true numerator is not known in both groups, we could not estimate a comparison in these subanalyses.

## DISCUSSION

In anterior cervical discectomy and arthrodesis, the achievement of stability is of obvious importance for the maintenance of long-term benefit. Nonunion has been associated

**TABLE 2. Stratified Analysis; Nonunion Rates Between Allograft and Cage, After Controlling for Two Variables**

	Allograft	Cage	P
One-level ACDF/Tobacco +	2.2% (22/1001)	5.5% (23/420)	0.0013
One-level ACDF/Tobacco –	1.6% (13/834)	2.8% (12/423)	0.1253
One-level ACDF/Diabetes +	3.1% (23/747)	6.2% (17/273)	0.0219
One-level ACDF/Diabetes –	1.1% (12/1088)	3.1% (18/570)	0.0029
Two-level ACDF/Tobacco +	3.0% (26/870)	7.3% (34/467)	0.0003
Two-level ACDF/Tobacco –	1.4% (11*/771)	4.8% (22/454)	0.0004
Two-level ACDF/Diabetes +	1.6% (11*/673)	8.6% (29/339)	<0.0001
Two-level ACDF/Diabetes –	1.9% (18/968)	4.6% (27/582)	0.0016
3+ level ACDF/Tobacco +	3.7% (12/324)	8.1% (12/147)	0.0416
3+ level ACDF/Tobacco –	NA	NA	NA
3+ level ACDF/Diabetes +	4.0% (11/272)	11.9% (15/126)	0.0032
3+ level ACDF/Diabetes –	NA	NA	NA
Tobacco +/Diabetes +	2.6% (25/957)	7.6% (30/396)	<0.0001
Tobacco +/Diabetes –	2.8% (35/1238)	6.1% (39/638)	0.0005
Tobacco –/Diabetes +	2.6% (19/735)	9.1% (31/342)	<0.0001
Tobacco –/Diabetes –	NA	NA	NA

The \* indicates that this number was less than 11 and thus not exactly known. In some cases, statistical analysis was still possible assuming the highest possible value. NA represents comparisons that could not be made because the numerators in both populations were less than 11.

ACDF indicates anterior cervical discectomy and fusion.

**TABLE 3. Stratified Analysis; Nonunion Rates Between Allograft and Cage, After Controlling for Three Variables**

	Allograft	Cage	P
One-level ACDF/Tobacco +/-Diabetes +	3.0% (13/430)	7.7% (11/143)	0.0159
One-level ACDF/Tobacco +/-Diabetes -	1.9% (11*/571)	4.7% (13/277)	0.0228
One-level ACDF/Tobacco -/Diabetes +	NA	NA	NA
One-level ACDF/Tobacco -/Diabetes -	NA	NA	NA
Two-level ACDF/Tobacco +/-Diabetes +	3.0% (11/368)	9.7% (18/186)	0.0009
Two-level ACDF/Tobacco +/-Diabetes -	3.2% (16/502)	7.5% (21/281)	0.0067
Two-level ACDF/Tobacco -/Diabetes +	3.6% (11*/305)	10.5% (16/153)	0.0034
Two-level ACDF/Tobacco -/Diabetes -	NA	NA	NA
3+ level ACDF/Tobacco +/-Diabetes +	NA	NA	NA
3+ level ACDF/Tobacco +/-Diabetes -	NA	NA	NA
3+ level ACDF/Tobacco -/Diabetes +	NA	NA	NA
3+ level ACDF/Tobacco -/Diabetes -	NA	NA	NA

The \* indicates that this number was less than 11 and thus not exactly known. In some cases, statistical analysis was still possible assuming the highest possible value. NA represents comparisons that could not be made because the numerators in both populations were less than 11.

ACDF indicates anterior cervical discectomy and fusion.

with poor clinical outcome and the need for revision surgery,<sup>10-12</sup> whether posterior or anterior, presents an additional risk to the patient.

The use of an intervertebral cage in anterior discectomy and arthrodesis has gained popularity.<sup>3</sup> Although the non-resorbable nature of the cage may allow for stability as the fusion mass forms, it may also represent a literal mechanical block for fusion formation. Fusion mass cannot form in the space occupied by the synthetic cage. With less endplate surface area and less intervertebral volume available for arthrodesis, we hypothesized that the use of a cage in ACDF would be significantly associated with the development of a nonunion.

Our study using the Humana data within the PearlDiver registry suggests that the use of an intervertebral cage in ACDF is statistically associated with a higher nonunion rate as compared to allograft. In every analysis and subanalyses, we observed a higher rate of nonunion in patients treated with a cage as opposed to allograft. These observations were statistically significant in 25 of the 26 possible permutations of analysis.

This finding is in contrast with prior literature. To date, there have been five studies that compared union rates in ACDF using cages *versus* bone graft and none of them were able to demonstrate a difference between the two techniques.<sup>5-9</sup> However, the sample size in these studies are low. Even when the data from these five studies are pooled, there are only 122 patients in the bone graft ACDF group and 147 patients in the cage group. This low combined sample size precludes sufficient analysis and control for confounding variables, whereas our study allows for a larger stratified analysis.

Our study observed that ACDF with structural allograft results in a significantly higher rate of arthrodesis than ACDF with a cage. Despite this finding, ACDF cages may continue to have a role in cervical spine arthrodesis. In situations where structural allograft may not be readily

available, cervical cages represent a reasonable alternative with a well-documented fusion rate, though perhaps not as high as allograft. However, as autologous iliac crest is widely available, a larger structured study with sufficient power, comparing the pros and cons of ACDF with cages and autologous iliac crest would be of great interest.

With any large database, there are weaknesses. The reliability of the reporting and coding is dependent upon multiple sources in an administrative data registry. We were unable to obtain radiographic evidence of nonunion for individual patients and instead relied on the diagnosis codes for nonunion, an important assumption we have made in this study. As this was an observational database study, we were also unable to determine the constitution of each cage placed, whether that be PEEK, titanium, mesh, or porous material. In our analysis, we stratified our initial population to account for the three most likely confounding variables for nonunion. It is entirely possible that other confounding variables exist and this may affect the analysis. Even with this large database, the nonunion patients whittled down to less than 11 patients in some subanalyses. One of the limitations of PearlDiver is when patient population size is less than 11, the true number is not revealed because of the potential for patient identification. We encountered this in some of our subanalyses and this did limit our ability to analyze the data, particularly in Tables 2 and 3 where we attempted to control for multiple confounders.

Future studies utilizing other data sources with sufficient sample size may be of value in further investigation. However, the PearlDiver data have been widely utilized in peer-reviewed publication.<sup>13,14</sup> To date, this study is the largest comparative study examining the fusion rates of ACDF using cages and structural bone graft. Our practice, like the majority of spine surgeons in North America,<sup>3</sup> is to utilize structural bone graft in ACDF. These data suggest that allograft, when available, may be a superior option than



the use of a cage in achieving arthrodesis in the cervical spine.

### ➤ Key Points

- ❑ In this study, both structural allograft and intervertebral cage groups experienced high fusion rates.
- ❑ When comparing nonunion rates, these data suggest the superiority of allograft in ACDF.
- ❑ While the use of a cage and nonstructural bone graft material remains an important surgical option, the use of allograft, when donor bone is available, may be preferable in achieving solid arthrodesis.

### Acknowledgment

The authors would like to thank Jeff France from the PearlDiver team his assistance throughout this project, as well as all anonymous reviewers for their feedback.

Supplemental digital content is available for this article. Direct URL citations appearing in the printed text are provided in the HTML and PDF version of this article on the journal's Web site ([www.spinejournal.com](http://www.spinejournal.com)).

### References

1. Bohlman HH, Emery SE, Goodfellow DB, Jones PK. Robinson anterior cervical discectomy and arthrodesis for cervical radiculopathy. Long-term follow-up of one hundred and twenty-two patients. *J Bone Joint Surg Am* 1993;75:1298–307.
2. Emery SE, Bohlman HH, Bolesta MJ, Jones PK. Anterior cervical decompression and arthrodesis for the treatment of cervical spondylotic myelopathy. Two to seventeen-year follow-up. *J Bone Joint Surg Am* 1998;80:941–51.
3. Yoon ST, Konopka JA, Wang JC, et al. ACDF graft selection by surgeons: survey of AOSpine members. *Global Spine J* 2017; 7:410–6.
4. Samartzis D, Shen FH, Matthews DK, et al. Comparison of allograft to autograft in multilevel anterior cervical discectomy and fusion with rigid plate fixation. *Spine J* 2003;3:451–9.
5. Bhadra AK, Raman AS, Casey AT, Crawford RJ. Single-level cervical radiculopathy: clinical outcome and cost-effectiveness of four techniques of anterior cervical discectomy and fusion and disc arthroplasty. *Eur Spine J* 2009;18:232–7.
6. Kim MK, Kim SM, Jeon KM, Kim TS. Radiographic comparison of four anterior fusion methods in two level cervical disc diseases: autograft plate fixation versus cage plate fixation versus stand-alone cage fusion versus corpectomy and plate fixation. *J Korean Neurosurg Soc* 2012;51:135–40.
7. Kim S-H, Lee JK, Jang JW, et al. Polyetheretherketone cage with demineralized bone matrix can replace iliac crest autografts for anterior cervical discectomy and fusion in subaxial cervical spine injuries. *J Korean Neurosurg Soc* 2017;60:211–9.
8. Lee C-H, Hyun SJ, Kim MJ, et al. Comparative analysis of 3 different construct systems for single-level anterior cervical discectomy and fusion: stand-alone cage, iliac graft plus plate augmentation, and cage plus plating. *J Spinal Disord Tech* 2013; 26:112–8.
9. Liu J-M, Xiong X, Peng AF, et al. A comparison of local bone graft with PEEK cage versus iliac bone graft used in anterior cervical discectomy and fusion. *Clin Neurol Neurosurg* 2017; 155:30–5.
10. Phillips FM, Carlson G, Emery SE, et al. Anterior cervical pseudarthrosis. Natural history and treatment. *Spine (Phila Pa 1976)* 1997;22:1585–9.
11. Lowery GL, Swank ML, McDonough RF. Surgical revision for failed anterior cervical fusions. Articular pillar plating or anterior revision?. *Spine (Phila Pa 1976)* 1995;20:2436–41.
12. Leven D, Cho SK. Pseudarthrosis of the cervical spine: risk factors, diagnosis and management. *Asian Spine J* 2016;10:776–86.
13. Myhre SL, Buser Z, Meisel HJ, et al. Trends and cost of posterior cervical fusions with and without recombinant human bone morphogenetic protein-2 in the US Medicare population. *Global Spine J* 2017;7:334–42.
14. Virk SS, Diwan A, Phillips FM, et al. What is the rate of revision discectomies after primary discectomy on a national scale?. *Clin Orthop Relat Res* 2017;475:2752–62.



## Technical Note

## PEEK-Halo effect in interbody fusion

Kevin Phan<sup>a,b</sup>, Jarred A. Hogan<sup>b</sup>, Yusuf Assem<sup>b</sup>, Ralph J. Mobbs<sup>a,b,\*</sup><sup>a</sup> Neuro Spine Clinic, Suite 7a, Level 7 Prince of Wales Private Hospital, Barker Street, Randwick, NSW 2031, Australia<sup>b</sup> NeuroSpine Surgery Research Group (NSURG), Sydney, NSW, Australia

## ARTICLE INFO

## Article history:

Received 19 July 2015

Accepted 24 July 2015

## Keywords:

Anterior lumbar interbody fusion

Bone-implant interface

Osseointegration

PEEK

Titanium

Titanium coating

## ABSTRACT

Recent developments have seen poly[aryl-ether-ether-ketone] (PEEK) being increasingly used in vertebral body fusion. More novel approaches to improve PEEK have included the introduction of titanium-PEEK (Ti-PEEK) composites and coatings. This paper aims to describe a potential complication of PEEK based implants relating to poorer integration with the surrounding bone, producing a “PEEK-Halo” effect which is not seen in Ti-PEEK composite implants. We present images from two patients undergoing anterior lumbar interbody fusion (ALIF). The first patient underwent an L5/S1 ALIF using a PEEK implant whilst the second patient underwent L4/L5 ALIF using a Ti-PEEK composite implant. Evidence of osseointegration was sought using CT imaging and confirmed using histological preparations of a sheep tibia model. The PEEK-Halo effect is demonstrated by a halo effect between the PEEK implant and the bone graft on CT imaging. This phenomenon is secondary to poor osseointegration of PEEK implants. The PEEK-Halo effect was not demonstrated in the second patient who received a Ti-PEEK composite graft. Histological analysis of graft/bone interface surfaces in PEEK versus Ti-PEEK implants in a sheep model further confirmed poorer osseointegration of the PEEK implant. In conclusion, the PEEK-Halo effect is seen secondary to minimal osseointegration of PEEK at the adjacent vertebral endplate following a PEEK implant insertion. This effect is not seen with Ti-PEEK implants, and may support the role of titanium in improving the bone-implant interface of PEEK substrates.

© 2015 Elsevier Ltd. All rights reserved.

## 1. Introduction

Since the approval of spinal implants for medical use there has been continuous development and advancement in their biomaterial construction. There are a number of properties which are sought when designing an ideal biopolymer for use in spinal implantation. These biopolymers aim to be strong, yet match the mechanical properties (elastic modulus) of bone; inert; biocompatible; and amenable to formation of a strong bone-implant interface (osseointegration) for long term fusion.

Traditional materials include titanium alloy cages, which achieve good rates of fusion [1]. However they have been associated with a number of disadvantages including (1) a higher subsidence rate of the cage into adjacent vertebrae [2]; (2) higher stiffness, reducing mechanical stimulation of the surrounding vertebral bone, and shielding the bone graft with implications on fusion in accordance with Wolff's Law [3]; (3) difficulties in radiological evaluation due to lack of radiolucency; and (4) subject to *in vivo* corrosion and hydrogen embrittlement [4].

Poly[aryl-ether-ether-ketone] (PEEK) biomaterials emerged and for use in medical applications as early as the 1980s [5], though they did not see widespread use as spinal cages until the late 1990s with the introduction of the Brantigan cage [6]. PEEK cages possess a number of mechanical advantages over traditional implants including (1) lower stiffness than titanium alloy, allowing better transfer of loading forces to the bone graft; (2) an elastic modulus much closer to that of cortical bone than titanium implants (4.3 GPa versus 18.6 GPa versus 110 GPa) [7]; and (3) minimisation of stress shielding compared to solid titanium implants [3].

PEEK implants also possess a number of cytological advantages, and have been shown to be as safe, non-cytotoxic and non-mutagenic as traditional implants [8,9] and have excellent *in vitro* and *in vivo* biocompatibility, that can be further improved with the addition of other materials including titanium [10,11].

Recent developments have seen PEEK being increasingly used in vertebral body fusion, mini-spine implants, as well as some pedicle based rod systems [12], interspinous spacers and disc arthroplasty [13,14]. More novel approaches to improve PEEK have included the introduction of titanium-PEEK (Ti-PEEK) composites and coatings [15].

\* Corresponding author. Tel.: +61 2 9650 4766.

E-mail address: [ralphmobbs@hotmail.com](mailto:ralphmobbs@hotmail.com) (R.J. Mobbs).

In order to optimise outcomes for patients, there must be continual evaluation of the properties of PEEK. This paper aims to describe a potential complication of PEEK based implants relating to poorer integration with the surrounding bone, producing a “PEEK-Halo” effect which is not seen in Ti-PEEK composite implants.

## 2. Technical note

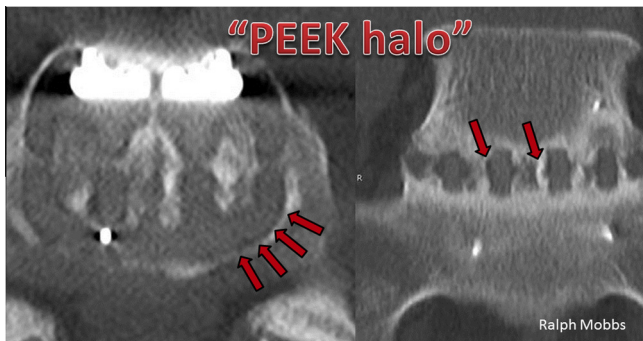Two patients were referred to the senior author for anterior lumbar interbody fusion procedures performed at L4/L5 and L5/S1, respectively. The first patient received a SYNFIX PEEK INTERBODY graft (SYNTHES, USA), whilst the second patient received a Ti-PEEK composite implant (REDMOND ALIF, A-SPINE ASIA, TAIWAN). CT images were captured at 12 month follow-up to assess for any evidence of poor osseointegration. Consent was obtained from both patients.

The histological methods have been described previously [19]. In brief, PEEK and Ti-sprayed PEEK implants were placed in a line-to-line manner in cortical bone and cancellous bone of adult sheep tibia using an established ovine model. Histomorphometric analysis was performed to assess the extent of osseointegration between the PEEK/composite material and cortical and cancellous implantation sites. Appropriate ethical approval was obtained for this study at the local hospital ethics board.

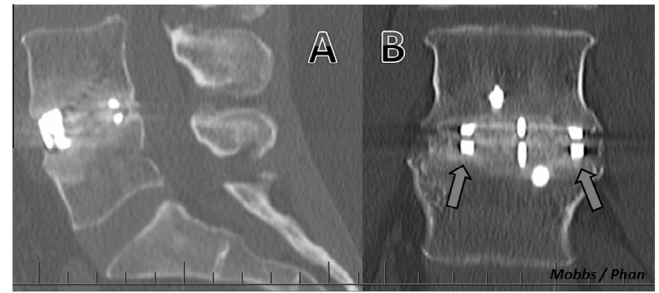
We describe in this article a phenomenon termed the “PEEK-Halo” effect. This phenomenon is represented by a halo effect between the PEEK implant and the bone graft on CT scan (Fig. 1). This phenomenon is secondary to poor osseointegration of PEEK implants, and has not been described in Ti-PEEK composites.

Figure 2 represents a Ti-PEEK composite implant which does not demonstrate the above described PEEK-Halo effect. We hypothesise that this is secondary to improved osseointegration of composite implants with the surrounding vertebral bone and bone graft placed within the cage device.

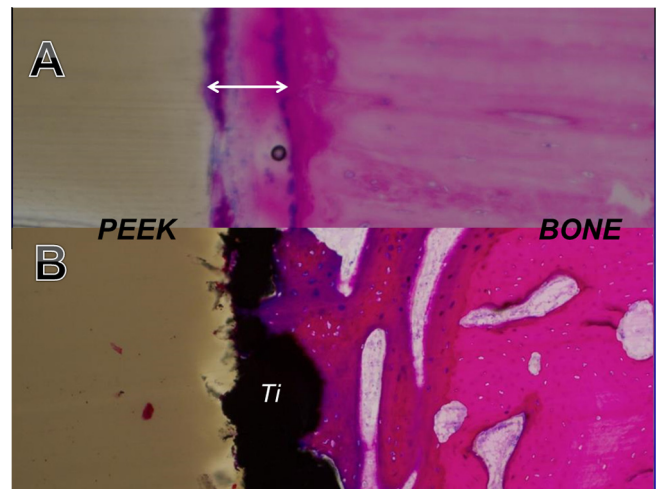
This effect was confirmed by a pre-clinical ovine tibia model histologically. In Figure 3A, a distinguishable fibrous tissue layer and gap has formed across the PEEK/bone interface of the inserted PEEK implants, corresponding to a radiolucent halo observed on CT scan. However the plasma sprayed titanium-coated implants illustrated in Figure 3B demonstrated on-growth and in-growth of bone across the Ti-PEEK/bone interface and the absence of a radiolucent rim on CT scan. Therefore, this histological analysis further substantiates the link between PEEK, fibrous tissue formation, reduced osseointegration and the development of the halo effect.



**Fig. 1.** (Left) Transverse and (right) coronal CT images at 12 months post L5/S1 anterior lumbar interbody fusion for discogenic low back pain. The presence of bridging bone between endplates confirms fusion through the construct with an excellent clinical outcome, however at the bone graft/poly[aryl-ether-ether-ketone] (PEEK) interface, a radiolucent rim is evident (delineated by the arrows) confirming no bone/PEEK integration, the so called “PEEK-Halo” effect.



**Fig. 2.** (A) Midsagittal and (B) coronal fine cut CT images at 12 months post L4/5 anterior lumbar interbody fusion demonstrating adjacent endplate sclerosis and the absence of radiolucency at the titanium-poly[aryl-ether-ether-ketone] (Ti-PEEK)–bone endplate interface (arrows).



**Fig. 3.** Histology of poly[aryl-ether-ether-ketone] (PEEK)/bone interface at 4 weeks post-implantation into a sheep tibia model. Histology processing of samples began with fixation in phosphate-buffered formalin, dehydration through increasing concentrations of ethanol (70% to 100%) and embedding in polymethylmethacrylate (PMMA) resin before being sectioned and stained with methylene blue and basic fuchsin. (A) Well-established rim of fibrous tissue (white arrow) between the PEEK implant and adjacent bone – the rim of fibrous tissue results in the halo effect seen on CT imaging. (B) Titanium (Ti)-PEEK/bone interface demonstrating on-growth and ingrowth of bone at the Ti-PEEK/bone interface, with no radiolucent rim evident on CT imaging. Adapted from Walsh et al. (2015) [19].

## 3. Comment

We hypothesise that there are a number of potential explanations for the existence of the PEEK-Halo effect seen between the vertebral bone and the PEEK implant. Implant materials generate peri-implant inflammatory factors, and it is these factors that are postulated to be responsible for the degree of osseointegration and therefore the rates of fusion long-term.

There is considerable debate however regarding the interaction between PEEK and osteoblastic differentiation. Sagomonyants et al. [16] showed that PEEK implants have comparable *in vitro* bone forming capacity to that of rough titanium. These data are supported by other studies which show that PEEK is capable of induction of osteoblast differentiation *in vitro* [17]. However, more recent studies have found that osteoblasts differentiate to a lesser degree when cultured on PEEK *versus* titanium surfaces, suggesting that the former has a lower level of support for osteogenic tissues [18]. If a Ti-PEEK composite does indeed allow better osteoblastic differentiation than PEEK, this could provide one possible explanation for the observed PEEK-Halo effect.

Another recent study demonstrated that plasma-sprayed titanium coating to PEEK implants improves the bone implant

interface. This study assessed shear strength in cortical sites at 4 and 12 weeks post-implantation in cancellous bone of adult sheep. The titanium coating was found to dramatically improve the shear strength at the bone-implant interface at 4 weeks, with further improvement at 12 weeks also observed when compared to PEEK alone [19].

A recent study compared *in vitro* and *in vivo* effects of PEEK versus PEEK with the addition of titanium via electron beam deposition. They found *in vitro* cellular responses of cell attachment, proliferation and osteoblastic differentiation to be superior in the Ti-PEEK implants compared to pure PEEK substrate. The *in vivo* bioactivity was also improved, with a significant difference observed in bone-in-contact ratio [20]. These findings, combined with those of Wu et al. [21] suggest better biocompatibility of Ti-PEEK implants, and give further weight to the presence of PEEK-Halo being secondary to poorer osseointegration of pure PEEK substrates.

#### 4. Conclusion

In summary we describe the PEEK-Halo effect which is seen secondary to minimal osseointegration of PEEK at the adjacent vertebral endplate following a PEEK implant insertion. This effect is not seen with Ti-PEEK implants, and may support the role of titanium in improving the bone-implant interface of PEEK substrates. Furthermore, the PEEK-Halo effect may provide incremental evidence for poor or reduced fusion rates on radiological imaging of patients who have received a pure PEEK implant.

#### Conflicts of Interest/Disclosures

The authors declare that they have no financial or other conflicts of interest in relation to this research and its publication.

#### Acknowledgement

We thank William R. Walsh for assistance with histomorphometric analysis.

#### References

- [1] Ray CD. Threaded titanium cages for lumbar interbody fusions. *Spine (Phila Pa 1976)* 1997;22:667–79 [discussion 679–80]. <http://www.ncbi.nlm.nih.gov/pubmed/9089940>.
- [2] Chen Y, Wang X, Lu X, et al. Comparison of titanium and polyetheretherketone (PEEK) cages in the surgical treatment of multilevel cervical spondylotic myelopathy: a prospective, randomized, control study with over 7-year follow-up. *Eur Spine J* 2013;22:1539–46. <http://dx.doi.org/10.1007/s00586-013-2772-y>.
- [3] Vadapalli S, Sairyo K, Goel VK, et al. Biomechanical rationale for using polyetheretherketone (PEEK) spacers for lumbar interbody fusion-A finite element study. *Spine (Phila Pa 1976)* 2006;31:E992–8. <http://dx.doi.org/10.1097/01.brs.0000250177.84168.ba>.
- [4] Rodrigues DC, Urban RM, Jacobs JJ, et al. In vivo severe corrosion and hydrogen embrittlement of retrieved modular body titanium alloy hip-implants. *J Biomed Mater Res B Appl Biomater* 2009;88:206–19. <http://dx.doi.org/10.1002/jbm.b.31171>.
- [5] Williams DF, McNamara A, Turner RM. Potential of polyetheretherketone (PEEK) and carbon-fibre-reinforced PEEK in medical applications. *J Mater Sci Lett* 1987;6:188–90. <http://dx.doi.org/10.1007/BF01728981>.
- [6] Brantigan JW, Steffee AD, Geiger JM. A carbon fiber implant to aid interbody lumbar fusion. Mechanical testing. *Spine (Phila Pa 1976)* 1991;16:S277–82. <http://www.ncbi.nlm.nih.gov/pubmed/1862425>.
- [7] Rho JY, Ashman RB, Turner CH. Young's modulus of trabecular and cortical bone material: ultrasonic and microtensile measurements. *J Biomech* 1993;26:111–9. <http://www.ncbi.nlm.nih.gov/pubmed/8429054>.
- [8] Katzer A, Marquardt H, Westendorf J, et al. Polyetheretherketone-cytotoxicity and mutagenicity in vitro. *Biomaterials* 2002;23:1749–59. <http://www.ncbi.nlm.nih.gov/pubmed/11950045>.
- [9] Hunter A, Archer CW, Walker PS, et al. Attachment and proliferation of osteoblasts and fibroblasts on biomaterials for orthopaedic use. *Biomaterials* 1995;16:287–95. <http://www.ncbi.nlm.nih.gov/pubmed/7772668>.
- [10] Wenz LM, Merritt K, Brown SA, et al. In vitro biocompatibility of polyetheretherketone and polysulfone composites. *J Biomed Mater Res* 1990;24:207–15. <http://dx.doi.org/10.1002/jbm.820240207>.
- [11] Rivard CH, Rhalmi S, Coillard C. In vivo biocompatibility testing of peek polymer for a spinal implant system: a study in rabbits. *J Biomed Mater Res* 2002;62:488–98. <http://dx.doi.org/10.1002/jbm.10159>.
- [12] Athanasakopoulos M, Mavrogenis AF, Triantafyllopoulos G, et al. Posterior spinal fusion using pedicle screws. *Orthopedics* 2013;36:e951–7. <http://dx.doi.org/10.3928/01477447-20130624-28>.
- [13] Delamarter RB, Murrey D, Janssen ME, et al. Results at 24 months from the prospective, randomized, multicenter Investigational Device Exemption trial of ProDisc-C versus anterior cervical discectomy and fusion with 4-year follow-up and continued access patients. *SAS J* 2010;4:122–8. <http://dx.doi.org/10.1016/j.esas.2010.09.001>.
- [14] Murrey DB, Janssen ME, Odum SM, et al. Two-year results of a randomized controlled clinical trial comparing ProDisc-C and anterior cervical discectomy and fusion. *SAS J* 2008;2:76–85. <http://dx.doi.org/10.1016/SASJ-2007-0124-RR>.
- [15] Rao PJ, Pelletier MH, Walsh WR, et al. Spine interbody implants: material selection and modification, functionalization and bioactivation of surfaces to improve osseointegration. *Orthop Surg* 2014;6:81–9. <http://dx.doi.org/10.1111/os.12098>.
- [16] Sagomonyants KB, Jarman-Smith ML, Devine JN, et al. The in vitro response of human osteoblasts to polyetheretherketone (PEEK) substrates compared to commercially pure titanium. *Biomaterials* 2008;29:1563–72. <http://dx.doi.org/10.1016/j.biomaterials.2007.12.001>.
- [17] Morrison C, Macnair R, MacDonald C, et al. In vitro biocompatibility testing of polymers for orthopaedic implants using cultured fibroblasts and osteoblasts. *Biomaterials* 1995;16:987–92. <http://www.ncbi.nlm.nih.gov/pubmed/8580262>. [Accessed June 5, 2015].
- [18] Olivares-Navarrete R, Hyzy SL, Slosar PJ, et al. Implant materials generate different peri-implant inflammatory factors: poly-ether-ether-ketone promotes fibrosis and microtextured titanium promotes osteogenic factors. *Spine (Phila Pa 1976)* 2015;40:399–404. <http://dx.doi.org/10.1097/BRS.0000000000000778>.
- [19] Walsh WR, Bertollo N, Christou C, et al. Plasma-sprayed titanium coating to polyetheretherketone improves the bone-implant interface. *Spine J* 2014;15:1041–9. <http://dx.doi.org/10.1016/j.spinee.2014.12.018>.
- [20] Han CM, Lee EJ, Kim HE, et al. The electron beam deposition of titanium on polyetheretherketone (PEEK) and the resulting enhanced biological properties. *Biomaterials* 2010;31:3465–70. <http://dx.doi.org/10.1016/j.biomaterials.2009.12.030>.
- [21] Wu X, Liu X, Wei J, et al. Nano-TiO<sub>2</sub>/PEEK bioactive composite as a bone substitute material: in vitro and in vivo studies. *Int J Nanomedicine* 2012;7:1215–25. <http://dx.doi.org/10.2147/IJN.S28101>.



# Articles in Review

“Five-fold Greater Risk of Pseudoarthrosis with PEEK”

Dr.Than – I Level Allograft vs PEEK; 127 Patients

“PEEK IBD Associated w 7-Fold Higher Rate of Pseudoarthrosis”

Dr.Than – Multi Level Allograft vs PEEK; 81 Patients

“5.32% Non-Union Rate for Cages; Allograft < 2%”

Pirkle et al – Allograft vs Cage: 6130 Patient Database

“Allograft Rate of Fusion 90.5%; PEEK – 77.4%”

Fatima et al. – Allograft vs PEEK; 6640 Patient Database

“The Likelihood of Revision was Nearly Double for Synthetics when Compared to Allograft”

Menon et al.; 8130 Patient Database

## ARTICLE IN REVIEW:

Greater risk of pseudoarthrosis using PEEK spacers vs structural allografts in 1-level ACDF

## ARTICLE IN REVIEW:

Greater risk of pseudoarthrosis using PEEK spacers vs structural allograft in multi-level ACDF

## ARTICLE IN REVIEW:

Higher nonunion rate using cages versus allografts in ACDF

## ARTICLE IN REVIEW:

Structural allografts provide better outcomes than PEEK cages in spinal fusion procedures

## ARTICLE IN REVIEW:

Lower revision rate with structural allografts vs synthetic cages in multilevel ACDF procedures

## ARTICLE IN REVIEW:

Lower revision rate with structural allografts vs synthetic cages in multilevel ACDF procedures

## ARTICLE IN REVIEW:

Lower revision rate with structural allografts vs synthetic cages in multilevel ACDF procedures

## ARTICLE IN REVIEW:

Lower revision rate with structural allografts vs synthetic cages in multilevel ACDF procedures

## ARTICLE IN REVIEW:

Lower revision rate with structural allografts vs synthetic cages in multilevel ACDF procedures

## ARTICLE IN REVIEW:

Lower revision rate with structural allografts vs synthetic cages in multilevel ACDF procedures

## ARTICLE IN REVIEW:

Lower revision rate with structural allografts vs synthetic cages in multilevel ACDF procedures

## ARTICLE IN REVIEW:

Lower revision rate with structural allografts vs synthetic cages in multilevel ACDF procedures

## ARTICLE IN REVIEW:

Lower revision rate with structural allografts vs synthetic cages in multilevel ACDF procedures

## ARTICLE IN REVIEW:

Lower revision rate with structural allografts vs synthetic cages in multilevel ACDF procedures

## ARTICLE IN REVIEW:

Lower revision rate with structural allografts vs synthetic cages in multilevel ACDF procedures

## ARTICLE IN REVIEW:

Lower revision rate with structural allografts vs synthetic cages in multilevel ACDF procedures

## ARTICLE IN REVIEW:

Lower revision rate with structural allografts vs synthetic cages in multilevel ACDF procedures

## ARTICLE IN REVIEW:

Lower revision rate with structural allografts vs synthetic cages in multilevel ACDF procedures

## ARTICLE IN REVIEW:

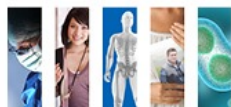Lower revision rate with structural allografts vs synthetic cages in multilevel ACDF procedures

## ARTICLE IN REVIEW:

Lower revision rate with structural allografts vs synthetic cages in multilevel ACDF procedures

## ARTICLE IN REVIEW:

Lower revision rate with structural allografts vs synthetic cages in multilevel ACDF procedures



**LifeNet Health**  
Saving Lives. Restoring Health. Giving Hope.

Copyright 2021 LifeNet Health® All rights reserved.



## ARTICLE IN REVIEW:

# Higher nonunion rate using cages versus allografts in ACDF

**PUBLICATION:** Spine Journal, March 2019

**TITLE:** Cages in ACDF are Associated with a Higher Nonunion Rate than Allograft. A Stratified Comparative Analysis of 6130 Patients.

**AUTHORS:** Pirkle S, Kaskovich S, Cook DJ, Ho A, Shi LL, Lee MJ.

**STUDY DESIGN:** Retrospective database review, 6130 patients.

**SUMMARY:** Anterior cervical discectomy and fusion (ACDF) is a common treatment for cervical degenerative disc disease (CDDD). Use of an interbody spacer provides support and promotes fusion. This retrospective review evaluated the rate of nonunion in 6130 patients who had undergone ACDF surgery using either structural allograft bone (n=4063) or synthetic cages (n=2067). After at least one year follow-up, overall nonunion rates were significantly higher in the cage group (5.32%) compared to the allograft group (1.97%;  $p < 0.01$ ). Increased rates of nonunion were consistently observed in the cage group regardless of confounding factors, such as levels treated, tobacco use, and diabetes. This study demonstrates a significantly greater risk of nonunion with the use of synthetic cages in ACDF procedures compared to structural allografts, supporting the use of structural allografts in cervical fusion procedures.

### Greater nonunion rate with synthetic cages:

Nonunion rates were significantly higher in the cage group (5.32%) than in the structural allograft group (1.97%;  $p < 0.01$ ).

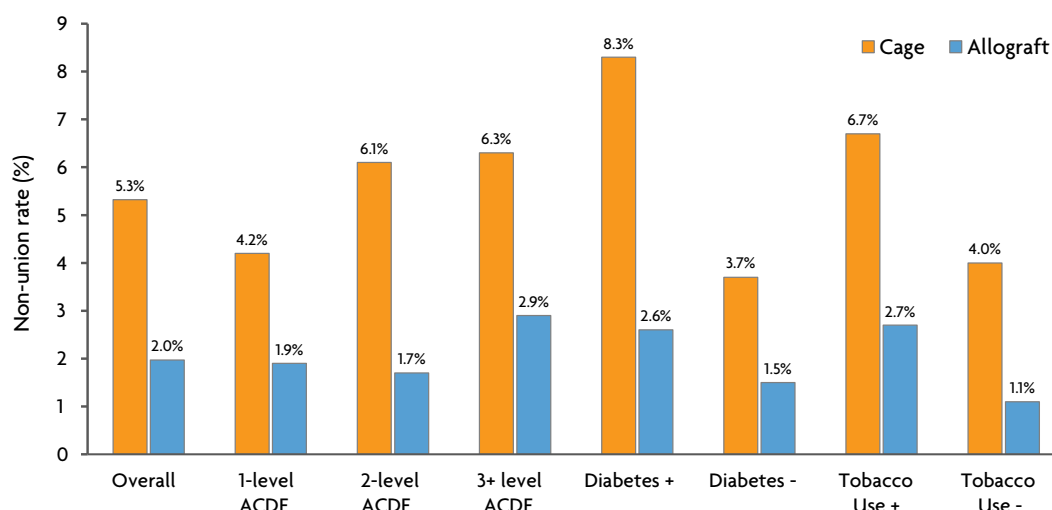
### Allograft outperformed cage regardless of confounding factors:

Cage group showed consistently higher nonunion rate regardless of confounding factors, such as levels treated, tobacco use, and diabetes.

### Structural allografts are an effective choice in ACDF:

The results suggest that allograft may be a superior option over a cage in achieving arthrodesis in the cervical spine.

Structural allografts have a lower rate of nonunion compared to synthetic cages.



68-20-286.00

LifeNet Health and the LifeNet Health logo are registered trademarks of LifeNet Health.

Third party trademarks used herein are the trademarks of their respective owners.

©2020 LifeNet Health, Virginia Beach, VA. All rights reserved.



## ARTICLE IN REVIEW:

# Greater risk of pseudarthrosis using PEEK spacers vs structural allografts in 1-level ACDF

**PUBLICATION:** Journal of Neurosurgery Spine, January 2019

**TITLE:** Five-fold higher rate of pseudarthrosis with polyetheretherketone interbody device than with structural allograft used for 1-level anterior cervical discectomy and fusion.

**AUTHORS:** Krause KL, Obayashi JT, Bridges KJ, Raslan AM, Than KD.

**STUDY DESIGN:** Retrospective, single center, multisurgeon, 127 patients.

**SUMMARY:** Anterior cervical discectomy and fusion (ACDF) is one of the most common treatments for cervical degenerative disc disease (CDDD). Long term success depends on the placement of an interbody spacer to provide support and promote fusion. Structural bone allografts and synthetic polyetheretherketone (PEEK) are two of the most common interbody spacers used in ACDF. This retrospective study evaluated the rates of pseudarthrosis and the need for revision surgery in 127 patients who had undergone a 1-level ACDF surgery using either structural allograft bone (n=71) or PEEK (n=56) interbody spacers. After at least 1 year follow-up, 29 out of 56 (52%) patients with PEEK implants demonstrated radiographic evidence of pseudarthrosis, which was 5-fold greater than that seen in patients with structural allografts (7 out of 71; 10%). Of these, 7 patients with PEEK implants (out of 29; 24%) required reoperation versus 1 patient with structural allografts (out of 7; 14%). This study demonstrates a significantly greater risk of pseudarthrosis ( $p < 0.001$ ) and increased rate of revision surgery ( $p = 0.01$ ) with the use of PEEK interbody spacers in 1-level ACDF procedures compared to structural allografts, supporting the use of structural allografts in cervical fusion procedures.

## Five-fold greater risk of pseudarthrosis with PEEK:

52% of patients with PEEK implants had radiographic pseudarthrosis, compared to 10% of those with structural allografts.

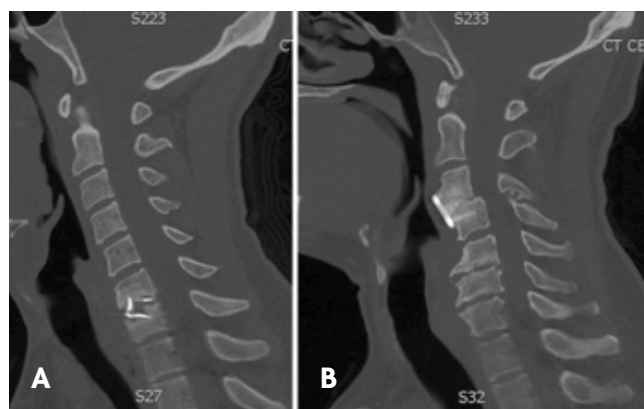
## Rate of subsequent revision nearly doubled with PEEK:

Of those with pseudarthrosis, only 1 patient with a structural allograft (14%) required revision surgery, compared to 7 patients in the PEEK group (24%).

## No significant differences between patient demographics:

Patients' age, sex, BMI, and tobacco use were similar between the two groups ( $p > 0.05$ ).

## Greater risk of pseudarthrosis with use of PEEK vs structural allograft



Radiographs showing use of (A) PEEK interbody spacer and pseudarthrosis and (B) structural allograft bone and fusion after 1 year.

Reprinted with permission from Krause et al. J Neurosurg Spine 2019.

68-20-287.00

LifeNet Health and the LifeNet Health logo are registered trademarks of LifeNet Health.  
©2019 LifeNet Health, Virginia Beach, VA. All rights reserved.

 **LifeNet Health®**  
Saving Lives. Restoring Health. Giving Hope.

## ARTICLE IN REVIEW:

# Structural allografts provide better outcomes than PEEK cages in spinal fusion procedures

**PUBLICATION:** World Neurosurgery, April 2020

**TITLE:** Structural Allograft versus Polyetheretherketone Implants in Patients Undergoing Spinal Fusion Surgery: A Systematic Review and Meta-Analysis

**AUTHORS:** Fatima N, Massaad E, Shankar GM, Shin JH.

**STUDY DESIGN:** Meta-analysis

**SUMMARY:** Interbody spacers, such as structural allografts or polyetheretherketone (PEEK) cages, are a popular alternative to autograft for spinal fusion. Comparisons of clinical success of these two materials are scarce. This systematic review of 7 studies included 6640 patients who underwent single-level or multilevel spinal fusion procedures with structural allografts (n=4250), or PEEK cages (n=2390). There were no significant differences in the patient demographics between the groups, including age, gender, BMI, and smoking status. By the final followup, the rate of fusion in the structural allograft group was 2.59-fold higher compared to the PEEK cages group (OR 2.59, 95% CI 1.02-6.57, p=0.05). Structural allografts were 61% less likely to result in pseudarthrosis (OR 0.39, 95% CI 0.15-0.98, p=0.05) and were 74% less likely to result in reoperation (OR 0.26, 95% CI 0.09-0.79, p=0.02). In an analysis of patients who underwent fusions in the cervical spine, those treated with structural allografts had 4.68-fold higher likelihood of fusion than patients treated with PEEK cages (OR 4.68, 95% CI 2.08-10.54, p=0.0002). These results align with previously reported fusion rates in the cervical spine. While prospective studies are needed, this analysis concludes structural allografts provide higher fusion rates and lower rates of pseudarthrosis compared to PEEK cages.

### Better fusion rates:

The pooled fusion rate in patients treated with structural allografts was 90.5% compared to 77.4% in patients with PEEK cages.

### Lower risk of pseudarthrosis and revision:

Patients treated with structural allografts were 61% less likely to have pseudarthrosis and 74% less likely to require reoperation.

### Greater rate of fusion in the cervical spine:

Patients with structural allografts had 4.68-fold higher likelihood of fusion than those with PEEK cages.

## Structural allografts provide better outcomes than PEEK cages

Parameter	Structural Allograft	PEEK
Patients (n)	4250	2390
Rate of pseudarthrosis	2.82%	8.91%
Rate of reoperation	0.07%	0.2%
Rate of fusion	90.5%	77.4%

Adapted from Table 3.

68-20-296.00

LifeNet Health and the LifeNet Health logo are registered trademarks of LifeNet Health.  
©2020 LifeNet Health, Virginia Beach, VA. All rights reserved.



## ARTICLE IN REVIEW:

# Lower revision rate with structural allografts vs synthetic cages in multilevel ACDF procedures

**PUBLICATION:** Global Spine Journal, August 2020

**TITLE:** Structural Allograft Versus Synthetic Interbody Cage for Anterior Cervical Discectomy and Fusion: A Comparison of 1-Year Outcomes from a National Database<sup>1</sup>

**AUTHORS:** Menon N, Turcotte J, Patton C.

**STUDY DESIGN:** Observational cohort study

**SUMMARY:** The TriNetX database, a global health research network, was used to identify 8,103 patients who had undergone single-level or multilevel anterior cervical discectomy and fusion (ACDF) procedures. The authors used these data to compare the rates of 1-year revision, pseudarthrosis, surgical site infection (SSI), and dysphagia between procedures using structural allograft and synthetic cage. Differences in patient age, gender, race, and comorbidities were controlled for using propensity score matching. In the single-level cohort, there was no significant difference ( $p>0.05$ ) in revision rates, pseudarthrosis rates, SSI, or dysphagia between patients who received structural allograft ( $n=1,528$ ) or synthetic cage ( $n=1,528$ ). In the multilevel cohort ( $n=3,510$ ; 50% synthetic cage/50% structural allograft), there was a significantly higher likelihood of revision surgery with synthetic cages compared to structural allografts (7.3% vs 3.8%, odds ratio=1.982,  $p<0.001$ ). However, there was significantly lower likelihood of dysphagia with synthetic cages (12.9% vs 15.9%, odds ratio=0.782,  $p=0.011$ ). There were no differences in SSI or the rate of pseudarthrosis. While the results were comparable in single-level procedures, the multilevel results were in line with previous reports in which higher rates of revisions were observed with synthetics.<sup>2-4</sup> Combined with reports of greater fusion rates<sup>4</sup>, structural allografts may be the superior option for ACDF procedures.

## Single-level procedures:

In single-level procedures, the likelihood of revision, pseudarthrosis, surgical site infection, and dysphagia were similar in both cohorts.

## Multilevel procedures:

The likelihood of revision was nearly double when using synthetics compared to structural allografts (7.3% vs 3.8%), but the likelihood of dysphagia was 3% lower with synthetics (12.9% vs 15.9%). There were no differences in surgical site infection or pseudarthrosis.

## References:

1. Menon N, Turcotte J, Patton C. Structural Allograft Versus Synthetic Interbody Cage for Anterior Cervical Discectomy and Fusion: A Comparison of 1-Year Outcomes From a National Database. Global Spine J. 2020 Aug 4;2192568220942217.
2. Teton ZE, Cheaney B, Obayashi JT, Than KD. PEEK interbody devices for multilevel anterior cervical discectomy and fusion: association with more than 6-fold higher rates of pseudarthrosis compared to structural allograft. J Neurosurg Spine. 2020 Jan 24;7. doi: 10.3171/2019.11.SPINE19788.
3. Krause KL, Obayashi JT, Bridges KJ, Raslan AM, Than KD. Fivefold higher rate of pseudarthrosis with polyetheretherketone interbody device than with structural allograft used for 1-level anterior cervical discectomy and fusion. J Neurosurg Spine. 2018 Oct 30;30(1):46-51. doi: 10.3171/2018.7.SPINE18531.
4. Fatima N, Massaad E, Shankar GM, Shin JH. Structural Allograft versus Polyetheretherketone Implants in Patients Undergoing Spinal Fusion Surgery: A Systematic Review and Meta-Analysis. World Neurosurg. 2020 Apr;136:101-109. doi: 10.1016/j.wneu.2020.01.006.

Significant differences  
in multilevel  
procedures

	Structural	Synthetic
Revision	3.8%	7.3%
Pseudarthrosis	No difference	
Surgical Site Infection	No difference	
Dysphagia	15.9%	12.9%

68-20-346.00

LifeNet Health and the LifeNet Health logo are registered trademarks of LifeNet Health.

©2021 LifeNet Health, Virginia Beach, VA. All rights reserved.

